



RAMA
UNIVERSITY

www.ramauniversity.ac.in

FACULTY OF NURSING



RAMA
UNIVERSITY

FOOT DISORDERS

Mr. M.Raghavendran M.Sc(N)
Professor
MSN Dept

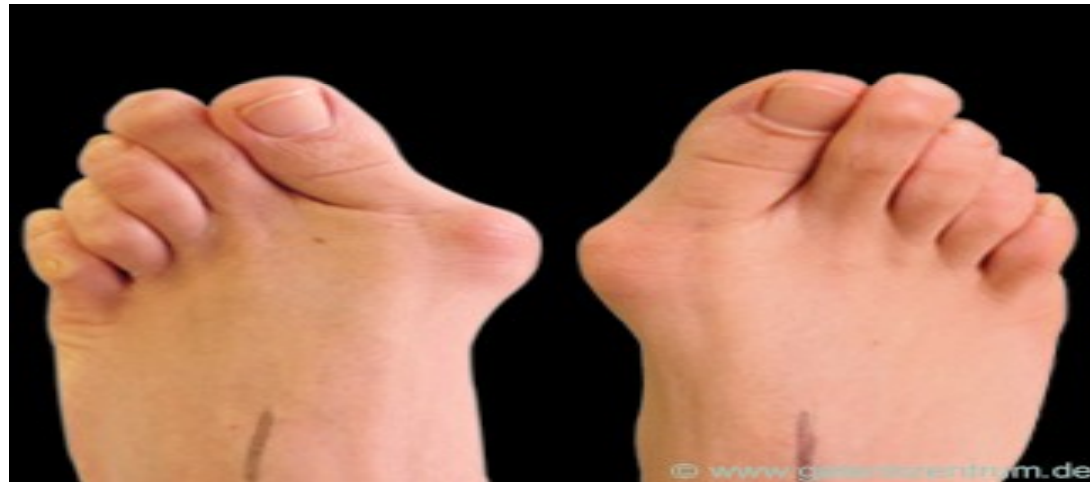FOOT

Foot is the platform that provides support for the weight of the body and absorbs considerable shock in ambulation

FOOT DISORDERS

- ***Fore Foot***
 - ***HALUS VALGUS*** (Bunion)
 - ***HALLUS RIGIDUS***
 - ***HAMMER TOE***
 - **MORTONS NEUROMA**

- Painful deformity of great toe consisting of lateral angulation of great toe towards second toe. Bony enlargement of medial side of first metatarsal head and formation of callus over bony enlargement.

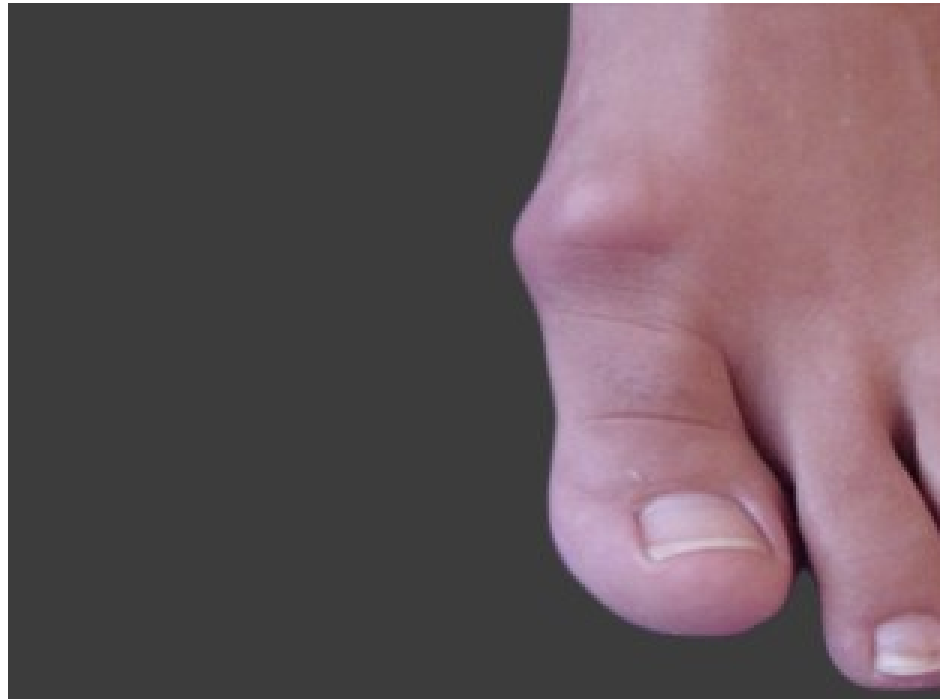

HALUS VALGUS (Bunion)

Treatment

- Wearing shoes with wide fore foot to relieve pressure on bursae sac
- Surgical removal of bursal sac and bony enlargement and correction of lateral angulation of great toe.

Painful stiffness of first meta torso phalangeal joint caused by osteoarthritis or local trauma



HALLUS RIGIDUS

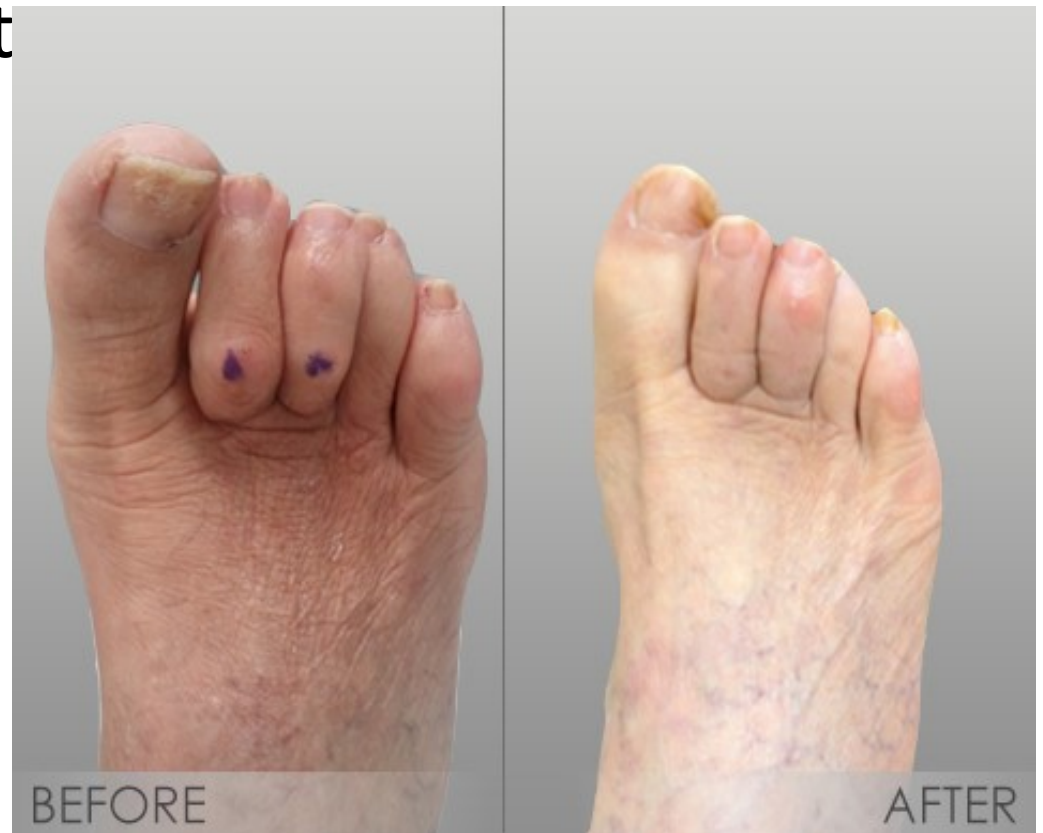Treatment

Intra articular corticosteroids and passive manual stretching

Surgery: joint fusion or Arthroplasty with silicone rubber implant.

Deformity of second through fifth toes
dorsiflexion of metatarsophalangeal joint
plantar flexion of proximal interphalangeal joint and callus on dorsum of proximal interphalangeal joint

HAMMER TOE



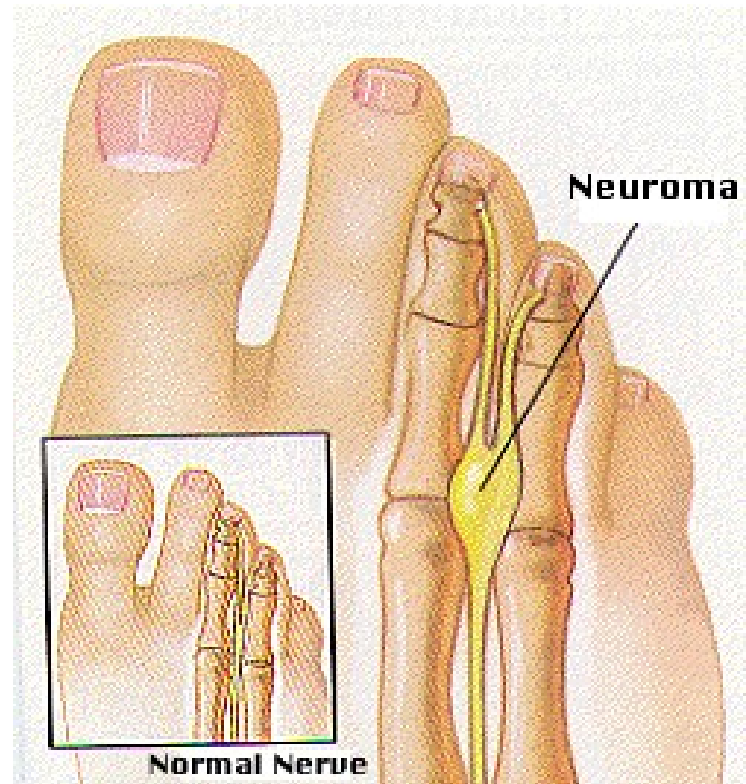
Treatment

Passive normal stretching of proximal interphalangeal joint and use of meta tarsal arch support

Surgery: Resection of base of middle phalanx and head of proximal phalanx and bringing raw bone end together.

Neuroma is a web space between III and IV metatarsal heads, causing sharp, sudden attacks of pain and burning sensation.

MORTONS NEUROMA

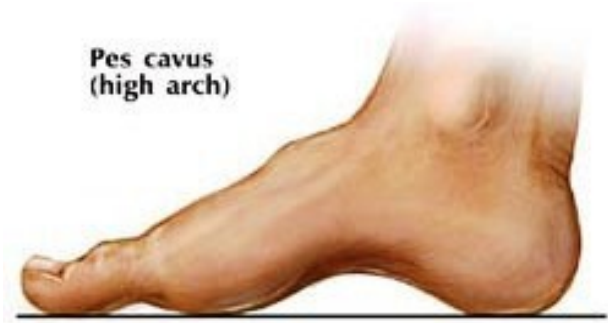


Treatment
Surgical excision is the only treatment

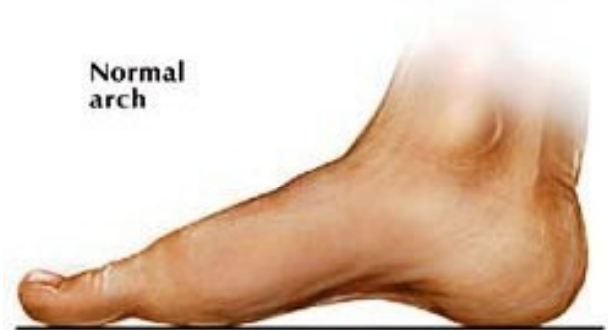Pes planus: (flat foot)

Pes cavus MIDFOOT

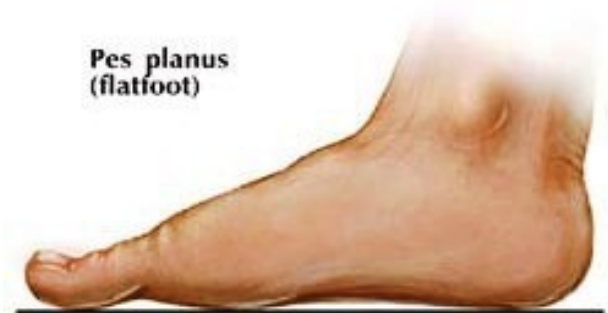
**Pes cavus
(high arch)**



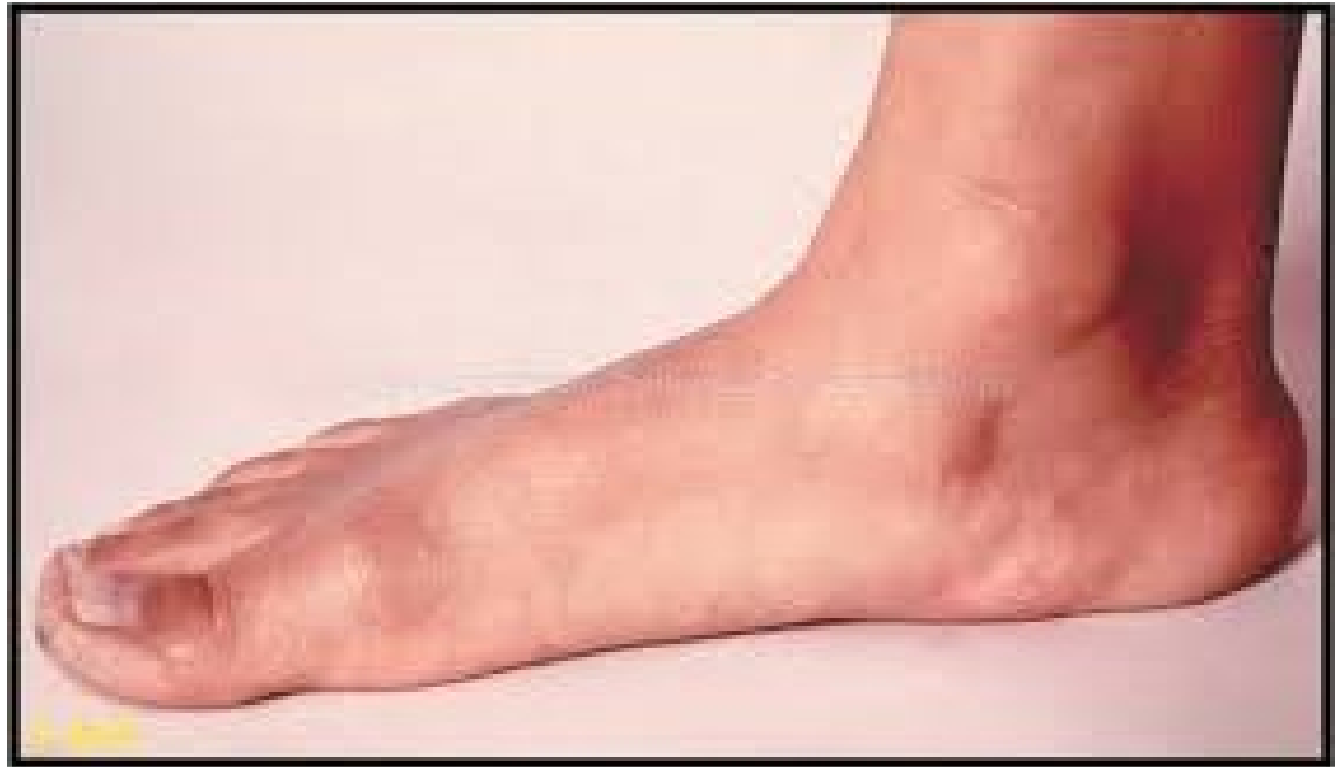**Normal
arch**



**Pes planus
(flatfoot)**



Loss of metatarsal arch causing pain in
foot or leg
PES PLANUS (*flat foot*)

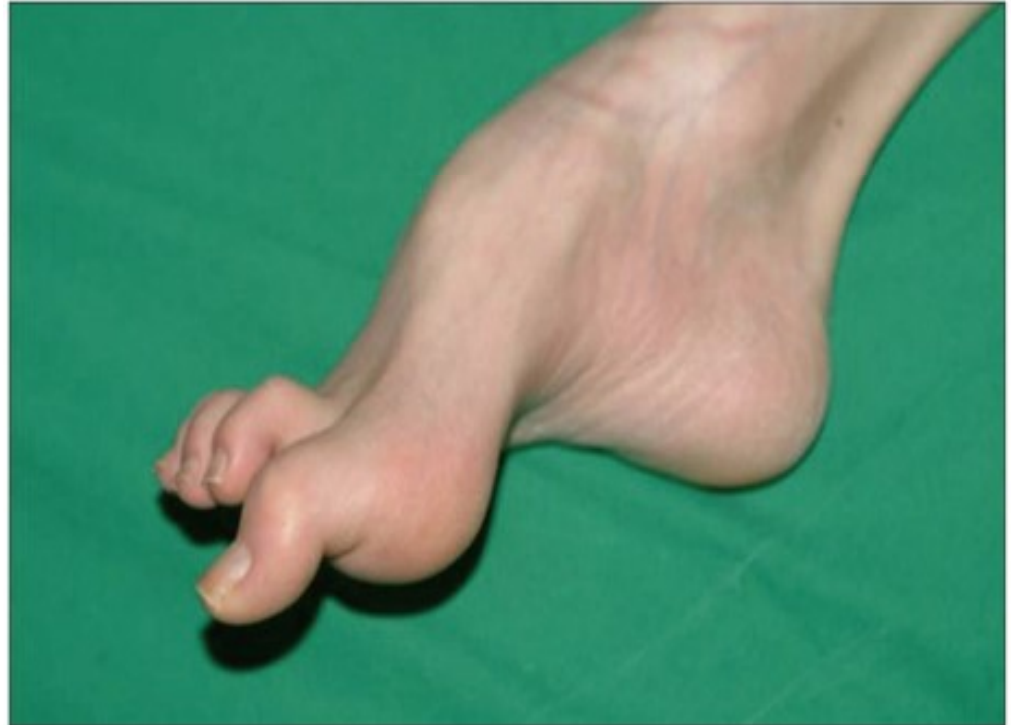

Treatment
Symptoms are relieved by use of resilient longitudinal arch support

Surgery: Triple Arthrodesis or fusion of subtalar joint

Elevation of longitudinal arch of foot
PES CAVUS
resulting from contracture of plantar fascia

Treatment: Manipulation and Casting
and Corrective Surgery



HIND FOOT

Painful Heals

Corn

Callus

Plantar Wart

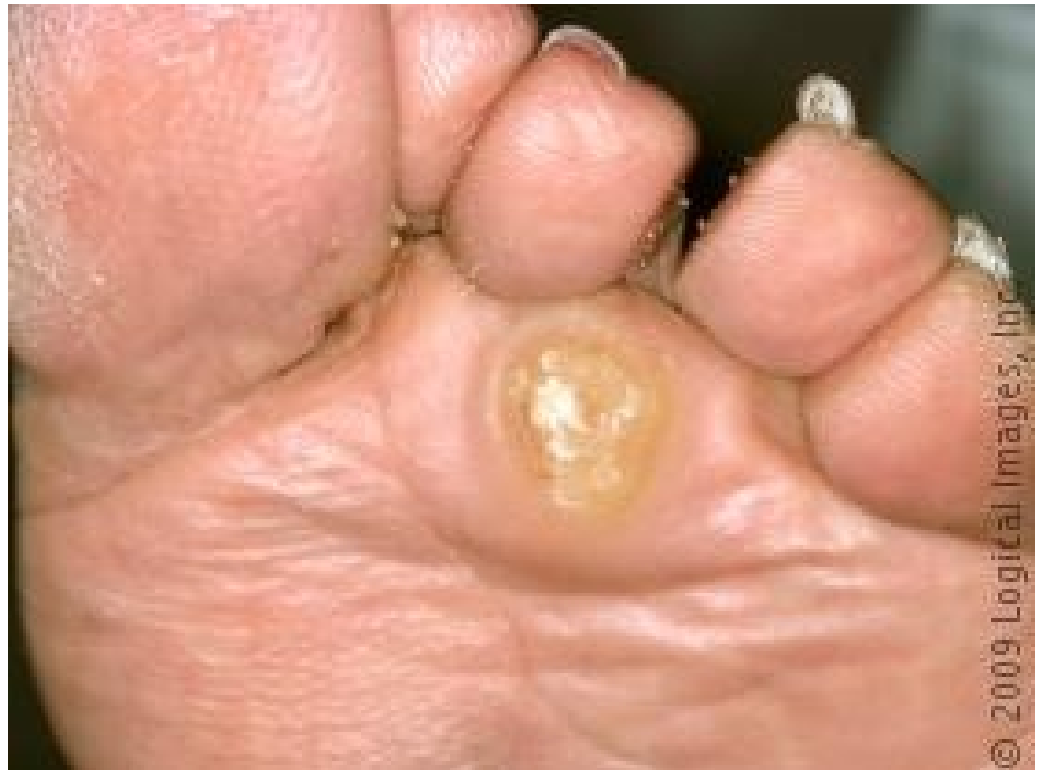PAINFUL HEALS

Complain of heel pain with weight bearing

Treatment:

- Corticosteroids are injected locally into infected bursa and sponge rubber heel cushion is used. Surgical excision is performed.

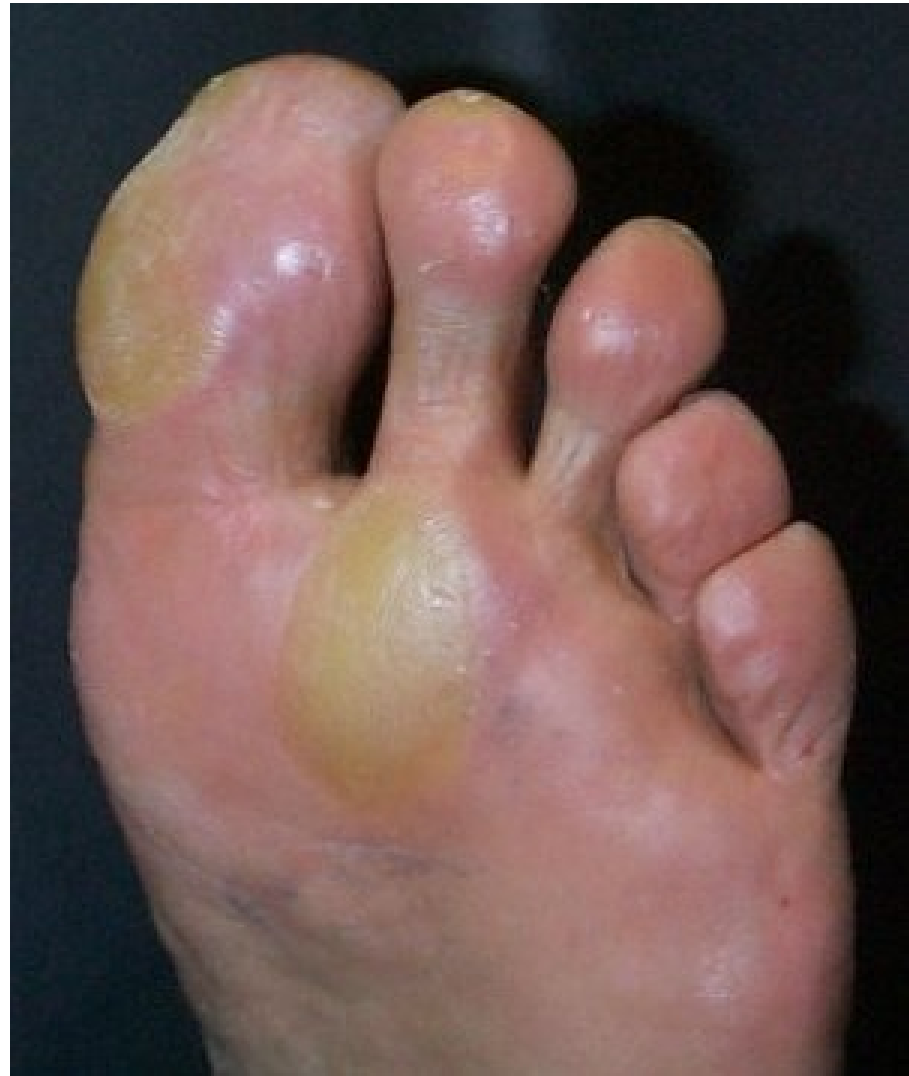Localized thickening of skin caused by continual pressure over bony prominences especially metatarsal head, frequently causing localized pain



Treatment

Corn is softened with warm water or preparations containing salicylic acid and trimmed with razor blade.

Similar formation to corn but covering
of wider area and usual location on weight
bearing part of foot.

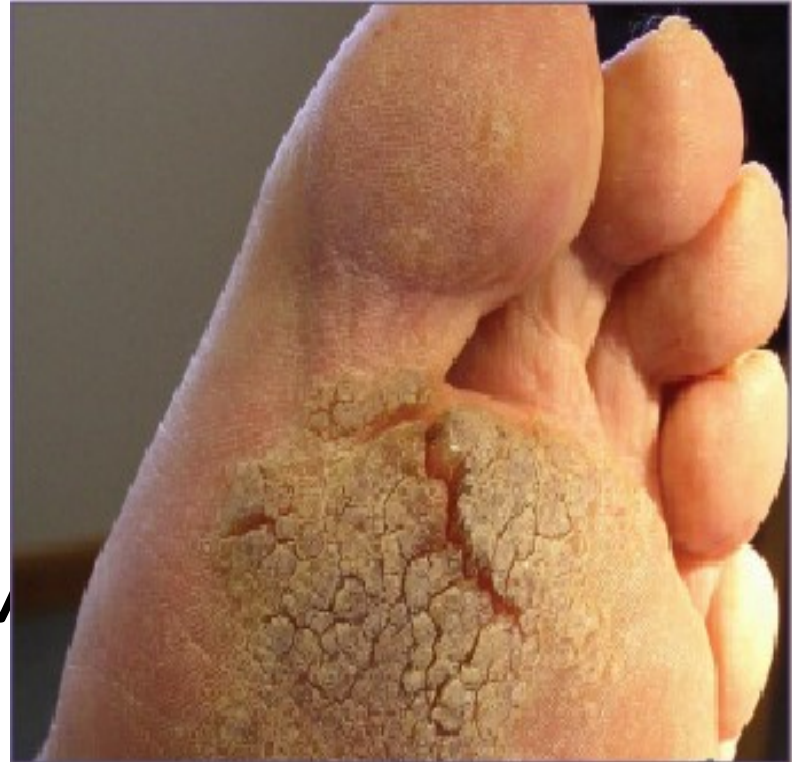

Treatment

Callus is softened with warm water or preparations containing salicylic acid and trimmed with razor blade.

Painful papillomatous growth caused by virus that may occur on any part of skin or sole of foot. They tend to cluster on pressure points.

PLANTAR W



Treatment

- Remedies containing salicylic acid
- Excision with electro coagulation
- Many disappear without treatment

HOME CARE

- Foot care should include
- Daily hygienic care
- Wearing clean stocking – long enough without shrinking
- Trimming of toe nails