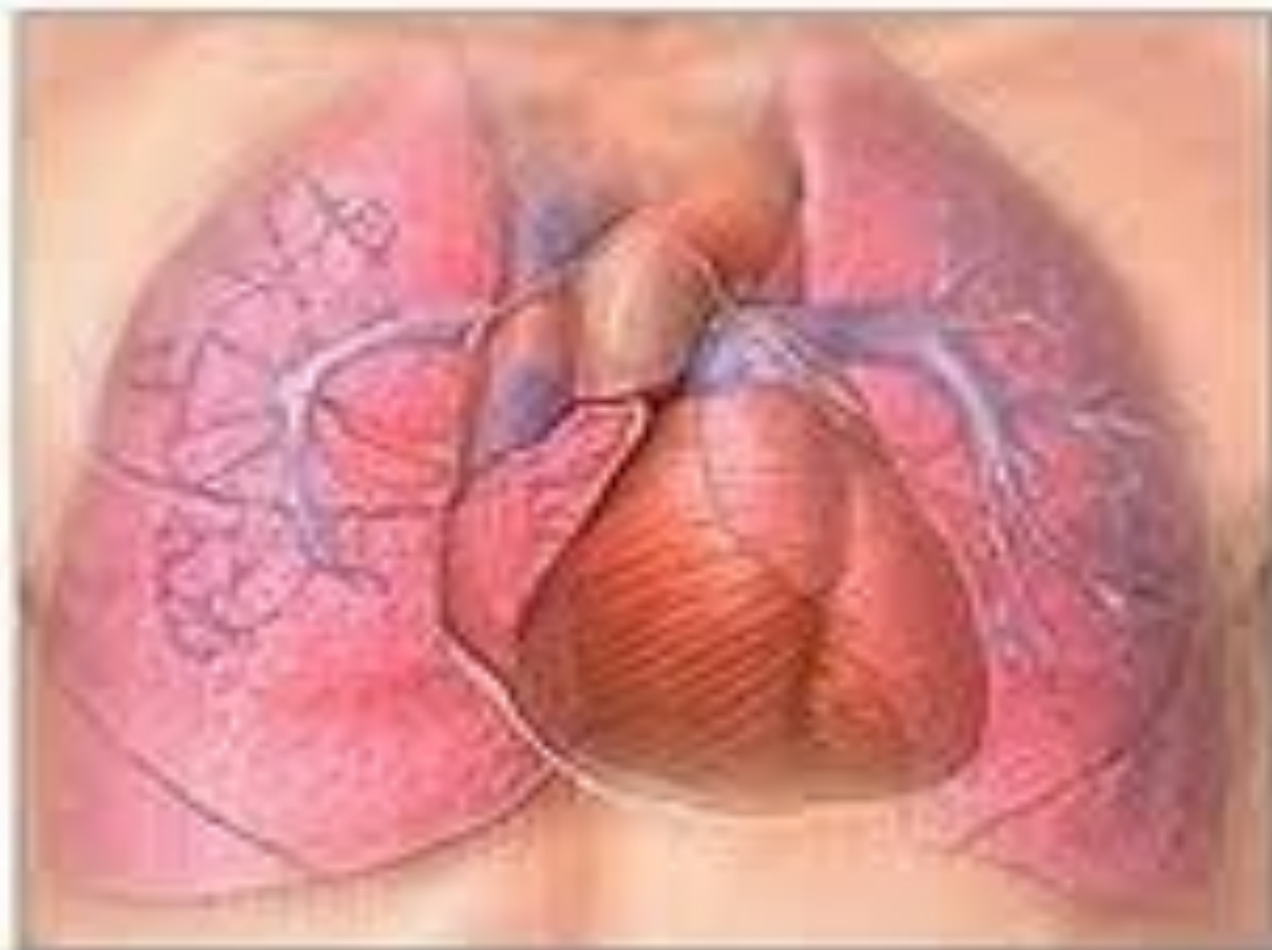
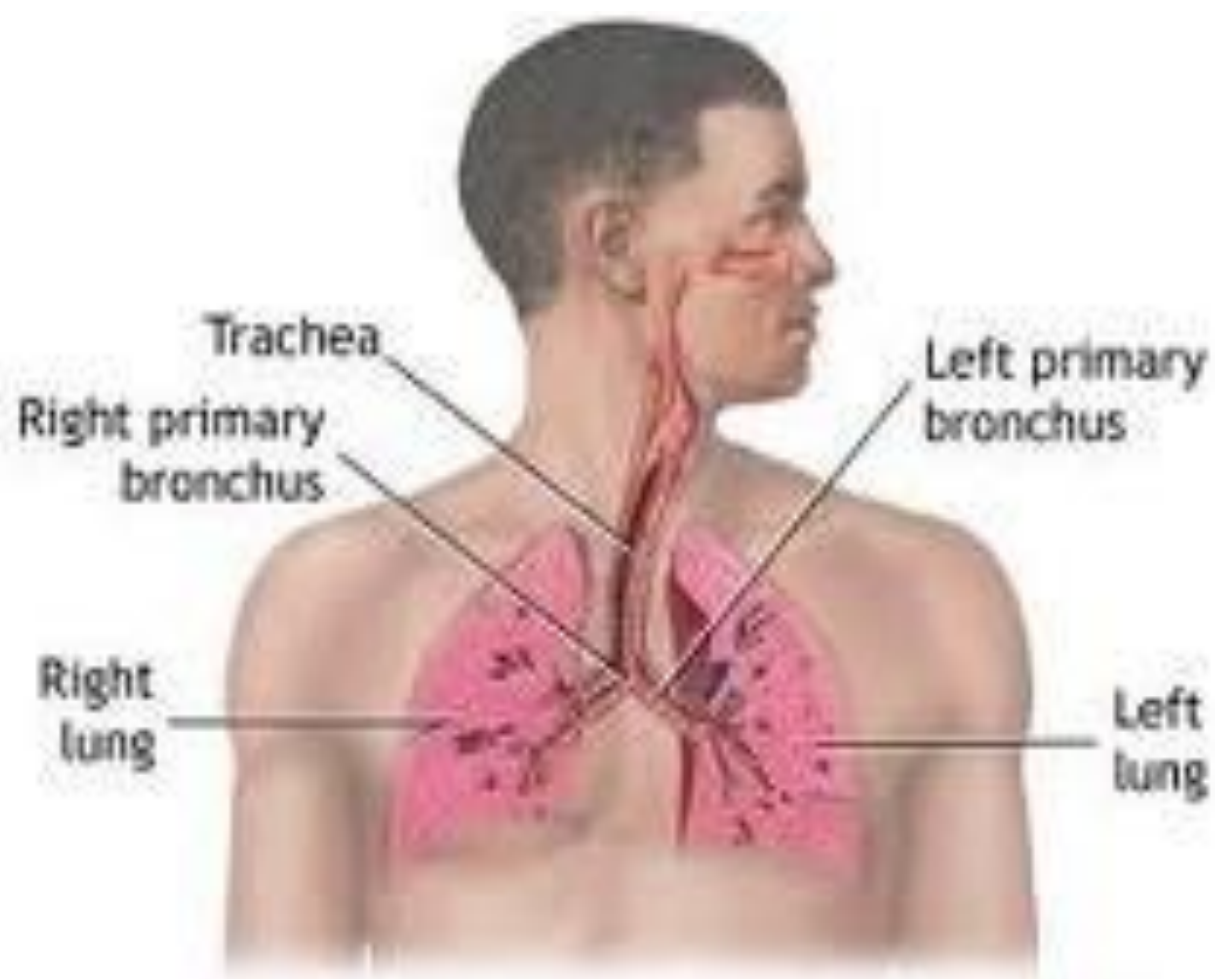


CORPULMONALE





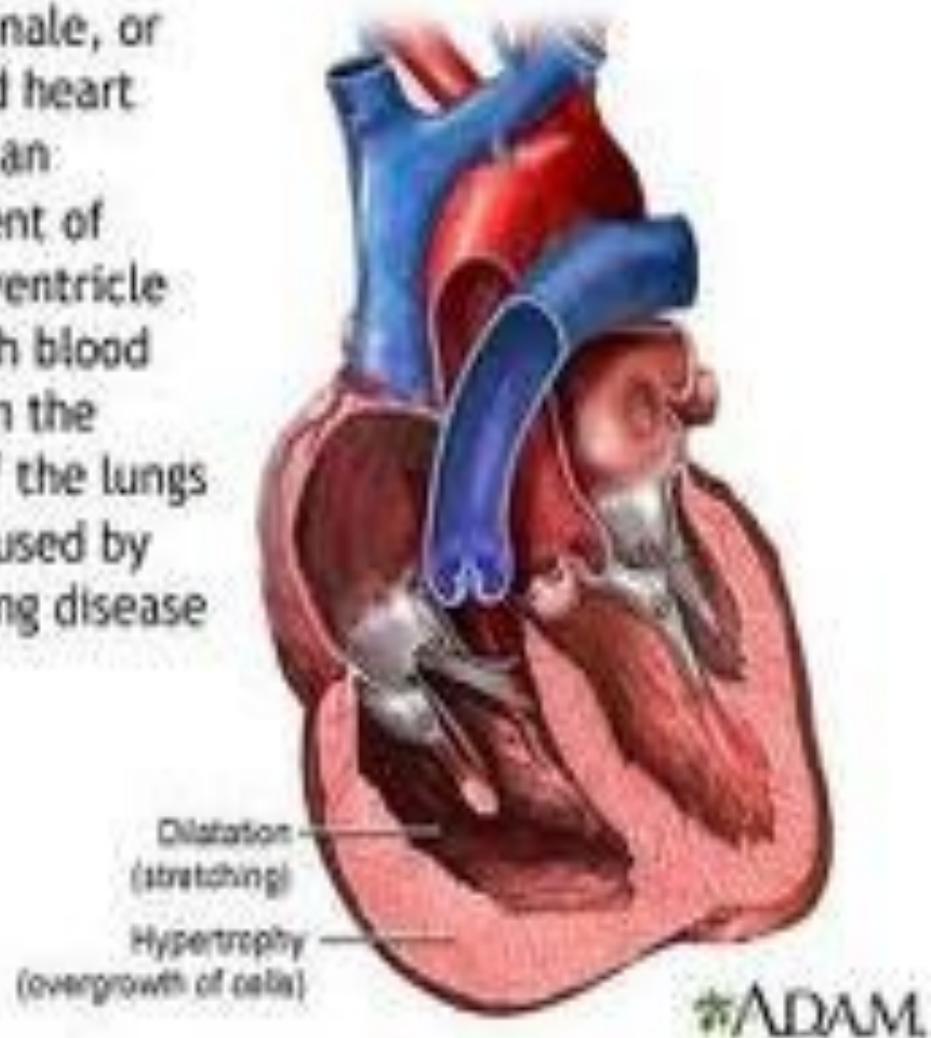
ADAM

DEFINITION OF COR PULMONALE

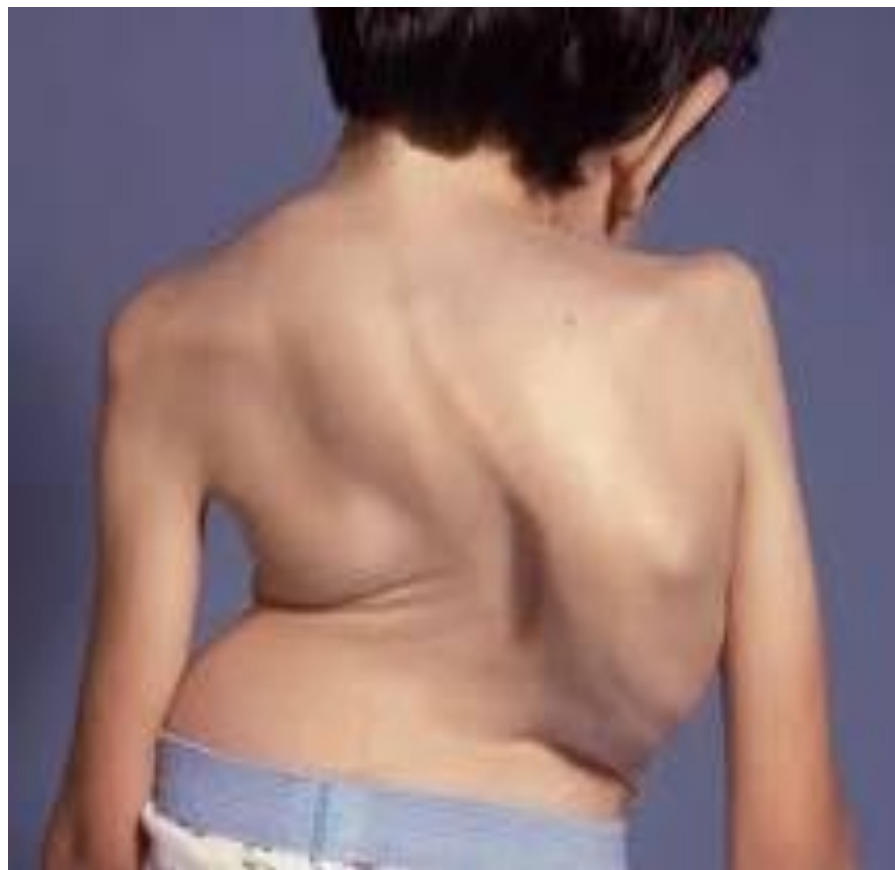- COR PULMONALE IS THE FAILURE OF THE RIGHT SIDE HEART CAUSED BY PROLONGED HIGH BLOOD PRESSURE IN THE PULMONARY ARTERY AND RIGHT VENTRICLE OF THE HEART.IT IS ALSO CALLED RIGHT SIDE HEART FAILURE.

CONT.....

Cor pulmonale, or right-sided heart failure, is an enlargement of the right ventricle due to high blood pressure in the arteries of the lungs usually caused by chronic lung disease



KYPHOSCOLIOSIS



CLINICAL FEATURES OF CORPULMONALE

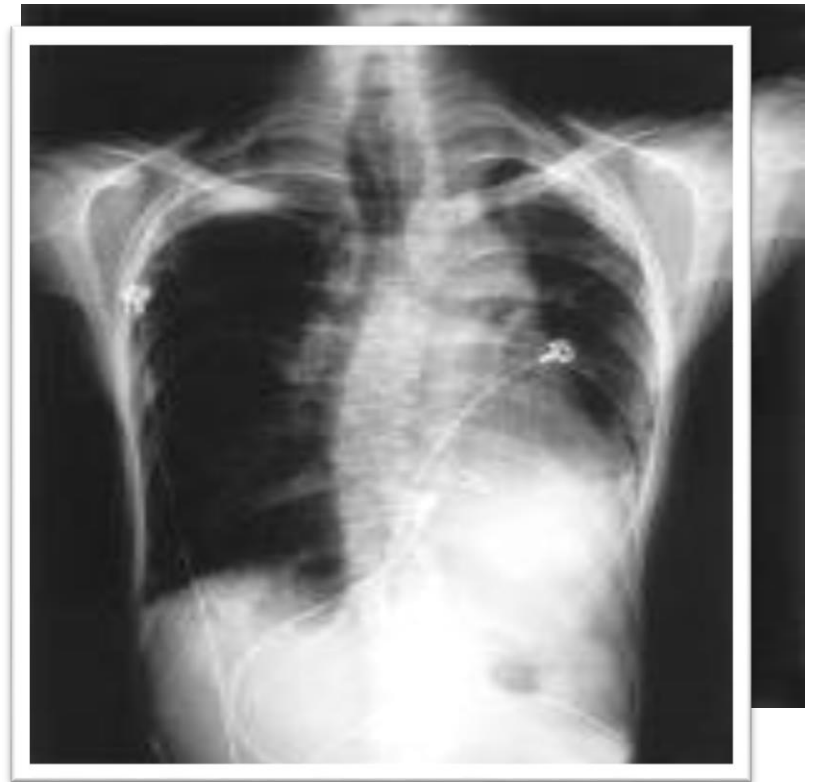
- CHEST DISCOMFORTE
- RETROSTERNAL OR SUBSTERNEL PAIN
- DYSPNOEA
- WHEEZING RESPIRATION
- CHRONIC PRODUCTIVE COUGH
- FATIGUE
- WEIGHT GAIN

CONT.....

- DISTENDED NECK VEIN
- BLUISH COLOUR TO THE SKIN
- SWELLING OF THE FEET OR ANKLES
- ASCITIS
- ABNORMAL HEART SOUND

DIAGNOSIC EVALUATION

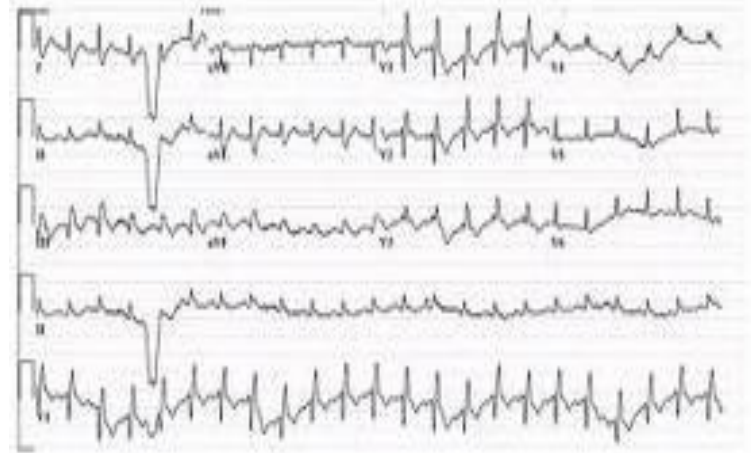- HISTORY COLLECTION
- PHYSICAL EXAMINATION
- CHEST X RAY



CONT.....

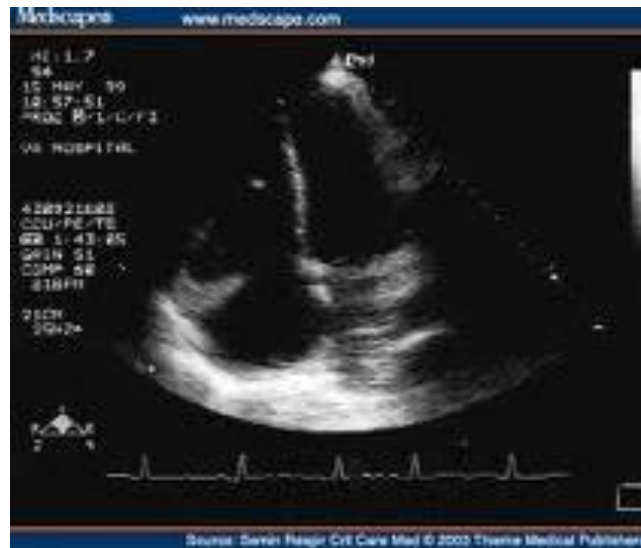- ELECTROCARDIOGRAM(ECG)

- PULMONARY FUNCTION TEST



CON.....

ECHOCARDIOGRAM



CONT....

- MEASUREMENT OF ABG

- CT SCAN OF THE CHEST

SURGICAL MANAGEMENT

- LUNG TRANSPLANTATION

NURSING INTERVENTIONS

❑ INEFFECTIVE BREATHING PATTERN DYSPNOEA RELATED TO SHORTNESS OF BREATH AND AIRWAY OBSTRUCTION

- ASSESS THE CONDITION OF THE PATIENT
- ASSIST THE CLIENT IN HIGH FOWLERS POSITION
- ADMINISTER LOW –FLOW OXYGEN THERAPY
- ADMINISTER BRONCHODILATORS IF ORDERD
- PROVIDE NEBULIZATION
- PROVIDE GOOD VENTILATION IN TO THE ROOM

CONT.....

- INEFFECTIVE AIRWAY CLEARANCE RELATED TO INCREASED MUCOUS PRODUCTION AND INEFFECTIVE COUGH

- MONITOR VITAL SIGNS

- MONITOR LUNG SOUND EVERY 4-8HOURS AND BEFORE AND AFTER COUGHING EPISODES

- PROVIDE STEAM INHALATION ,NEBULIZATION

- PROVIDE CHEST PHYSICAL THERAPY,IF NEEDED

- GIVE ORAL CARE TO REMOVE SECRETIONS IN MOUTH

CONT.....

- IMPAIRED GAS EXCHANGE RELATED TO EXCESS FLUID IN LUNGS ,INCREASED PULMONARY VASCULAR RESISTANCE
 - MONITORING ABG VALUES AND OXYGEN SATURATION
 - ADMINISTER CONTINUOUS LOW-FLOW OXYGEN AS CORRECT TO HYPOXIA
 - ASSIST THE PATIENT IN TO HIGH FOWLERS POSITION
 - ADMINISTER BRONCHODILATORS FOR RELAX BRONCHIAL SMOOTH MUSCLE
 - AVOID OPIOIDS,SEDATIVES BECAUSE THESE MEDICATIONS ARE RESPIRATORY DEPRESENTS AND CAN FURTHER IMPAIR VENTILATION

CONT.....

- EXCESS FLUID VOLUME RELATED TO RIGHT SIDE HEART FAILURE

- WATCH ALTERATIONS IN ELECTROLYTE LEVELS ESPECIALLY POTTASSIUM ,WHICH CAN BE LEAD TO DISTURBANCE OF CARDIAC RHYTHM

- MONITOR ECG

- RESTRICT SODIUM INTAKE BASED ON FLUIDD RETENTION

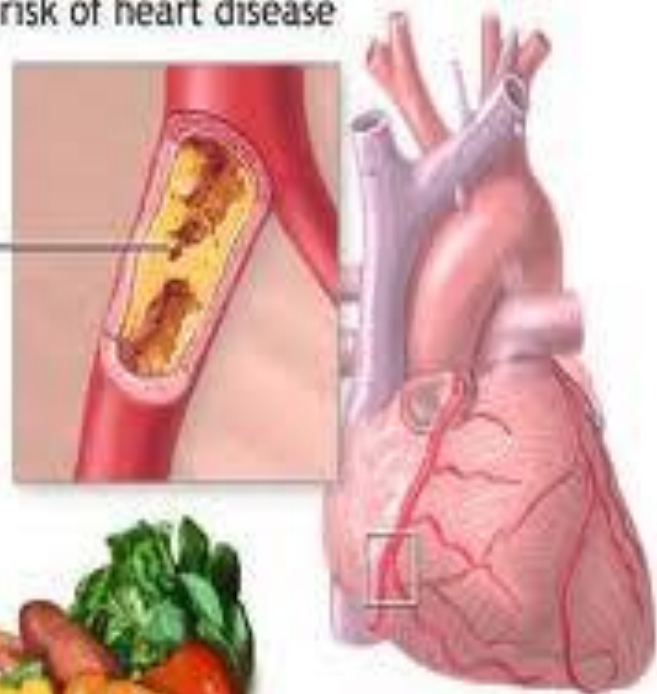
- LIMIT PHYSICAL ACTIVITY

CONT.....

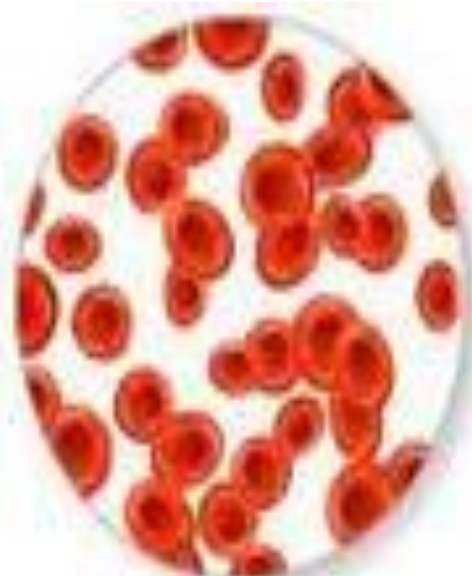- IMBALANCED NUTRITION LESS THAN BODY REQUIREMENT RELATED TO COUGH,DYSPNOEA
 - ASSIST THE PATIENT WITH MOUTH CARE BEFORE MEALS AND AS NEEDED
 - PROVIDE SMALL FREQUENT MEALS WITH HIGH PROTIEN AND CALORIES
 - ADVISE THE PATIENT TO AVOID GAS FORMING FOOD SUCH AS POTTATO ,CABBAGE ETC
 - ADIVISE HYPOXEMIC PATIENT TO USE OXYGEN VIAL NASAL CANULA DURING MEALS
 - MONITOR THE CLIENTS FOOD INTAKE AND WEIGHT

Quitting smoking, a healthy diet and exercise may reduce your risk of heart disease

Plaque in
coronary
artery



ADAM

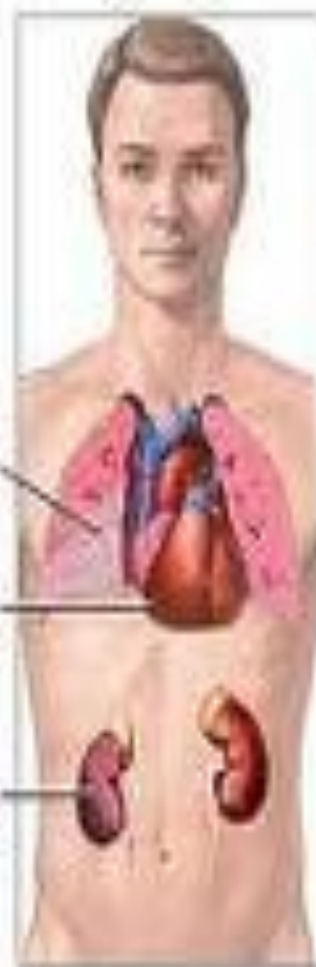

High numbers of RBCs may indicate conditions such as:

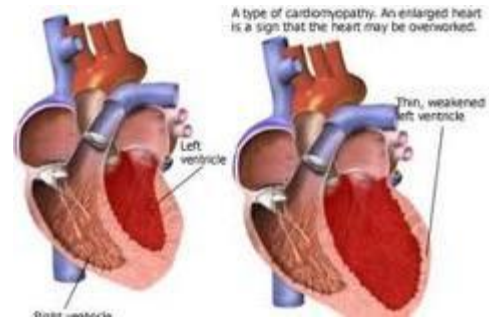
Pulmonary fibrosis

Cor pulmonale

Renal disease



ADAM



A type of cardiomyopathy. An enlarged heart is a sign that the heart may be overworked.

ASSIGNMENT

- Mr X 50 YEARS AGE MAN ADMITTED IN MICU WITH THE C/O CHEST DISCOMFORT,DYSPNEA,PERIPHERAL EDEMA AND DISTENDED NECK VEIN.HE IS HAVING THE H/O COPD SINCE 5 YEARS.NOW THE DOCTOR DIAGNOSED AS RIGHT SIDE HEART FAILURE .

PREPARE A NURSING CARE PLAN FOR HIM.

THANK YOU