



RAMA
UNIVERSITY

www.ramauniversity.ac.in

FACULTY OF NURSING



RAMA
UNIVERSITY

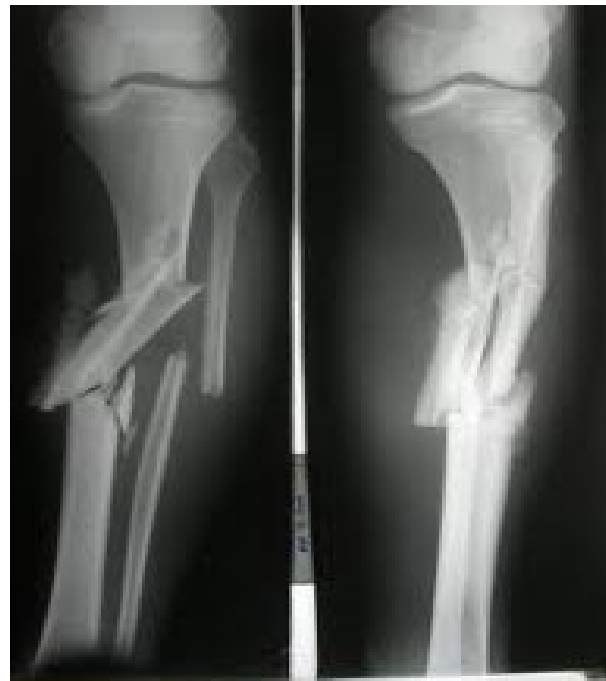FRACTURE

Mr. M.Raghavendran M.Sc(N)
Professor
MSN Dept

Fracture

Definition

A fracture is a disruption or discontinuity in bone fragment or in the structure of bone.



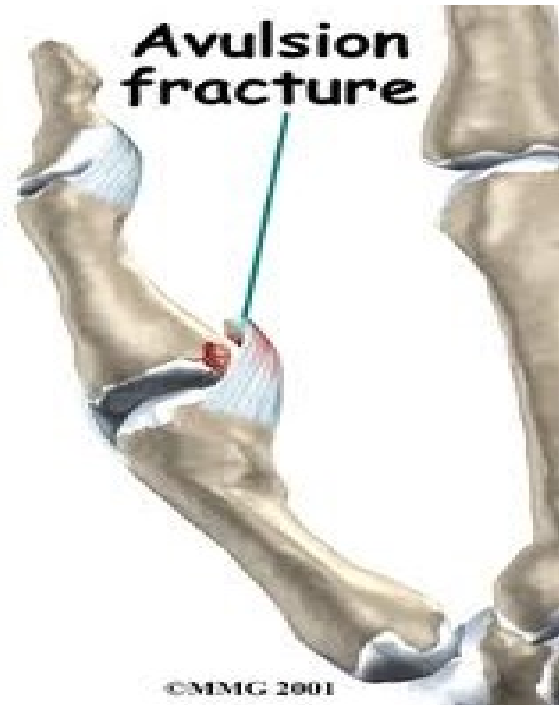Classification

- Type
- Communication or Non Communication with External Environment
- Anatomic Location of Fracture

TYPES OF FRACTURE

Avulsion Fracture:

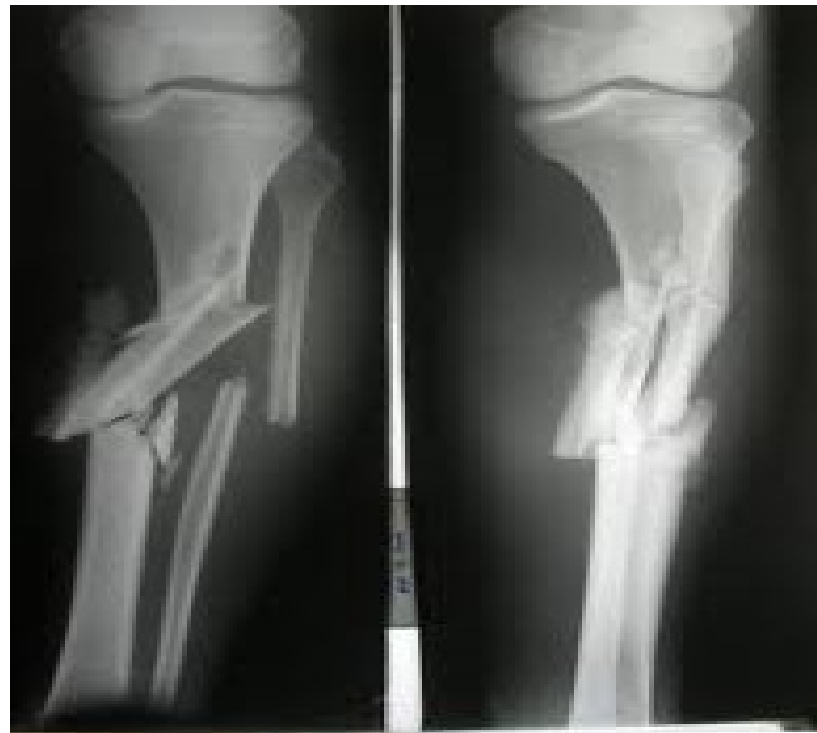Is a fracture of bone resulting from strong pulling effect of tendons or ligaments at the bone attachment



Cont...

Communitated Fracture:

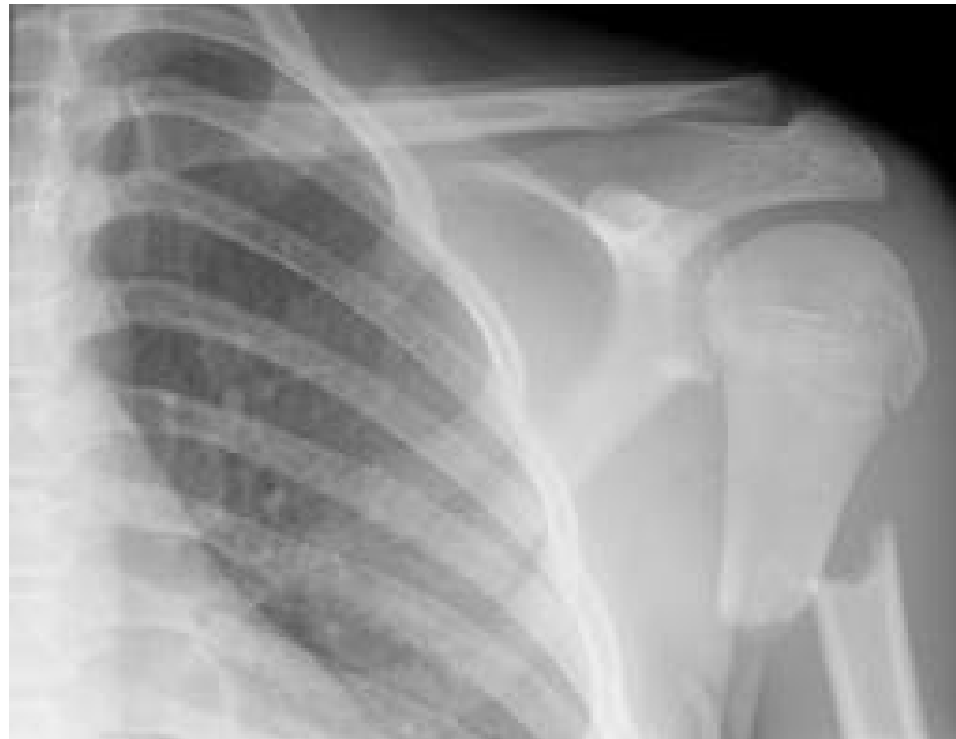It is a fracture with more than two fragments, the smaller one appear to be floating



Cont...

Displaced Fracture:

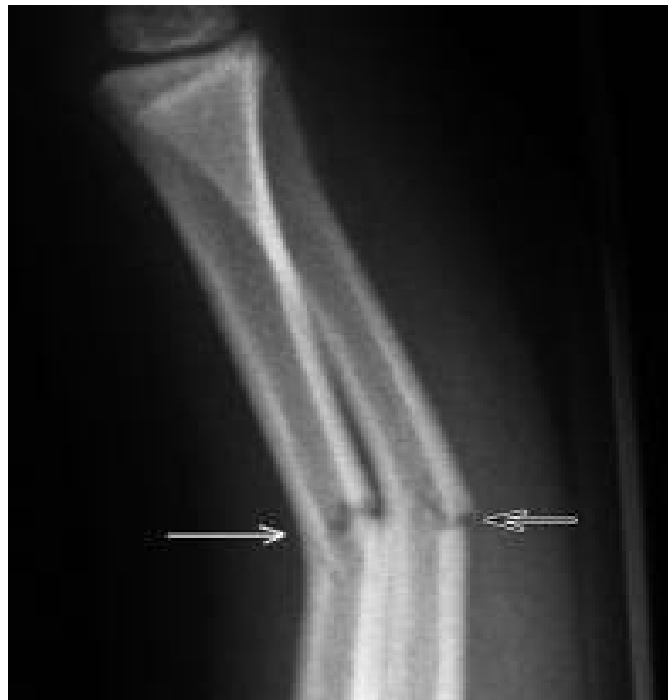It involves a displaced fracture fragment that overrides the other bone fragment.



Cont...

Greenstick Fracture :

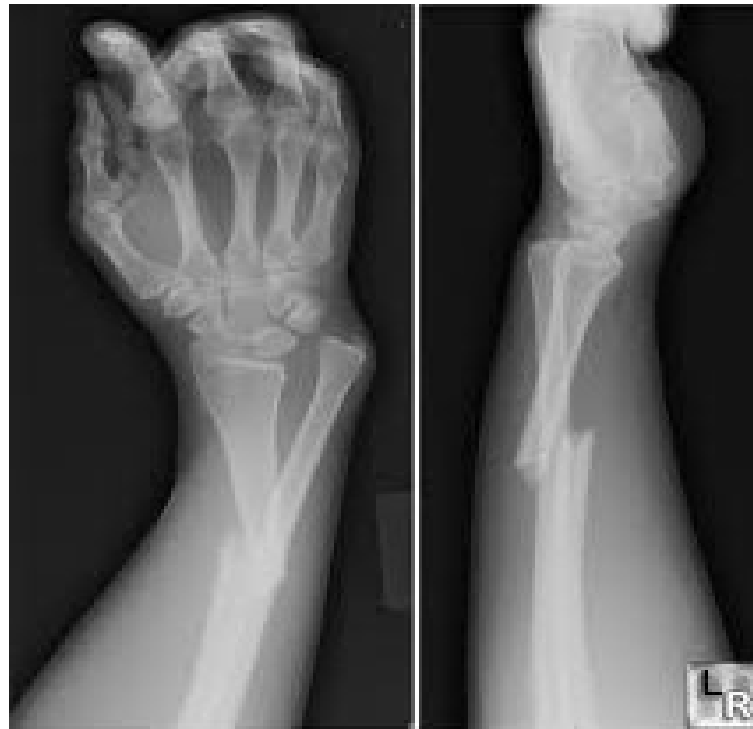it is an incomplete fracture with one side splintered and other side bent.



Cont...

Impacted Fracture:

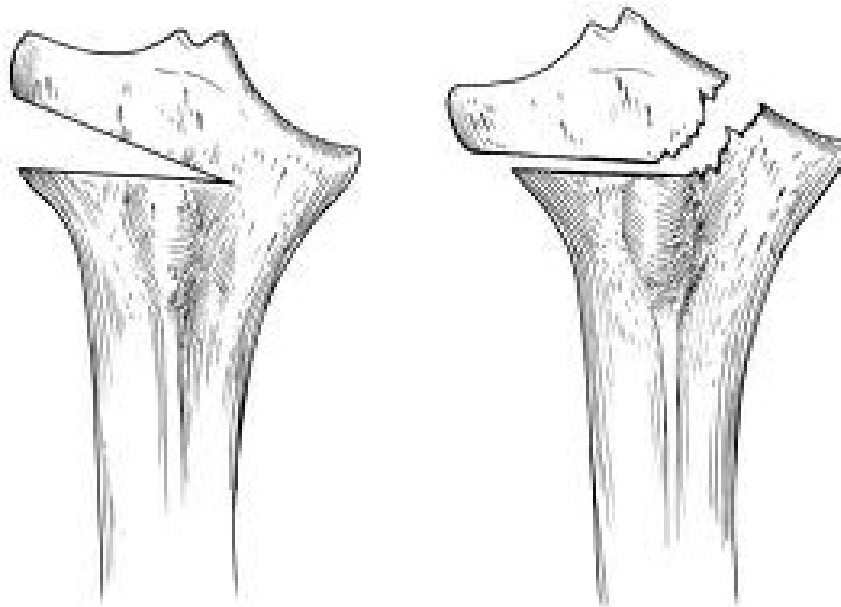
It is a comminuted fracture in which more than two fragments are driven into each other.



Cont...

Intra Articular:

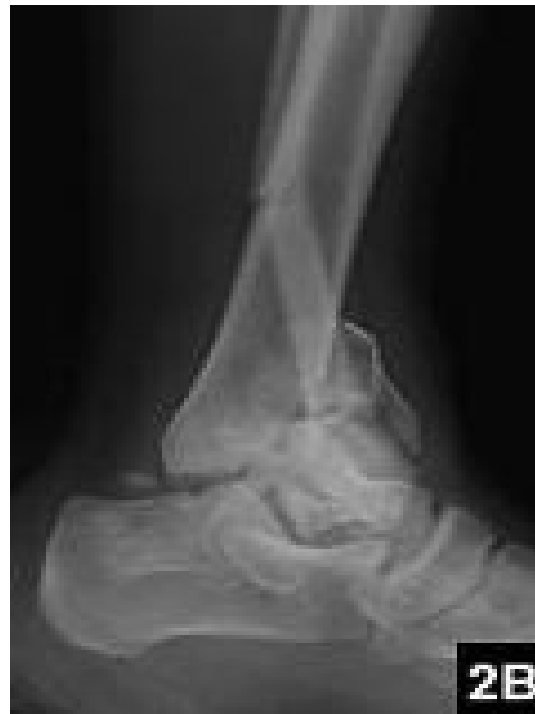it is a fracture extending to the articular surface of the bone.



Cont...

Longitudinal Fracture:

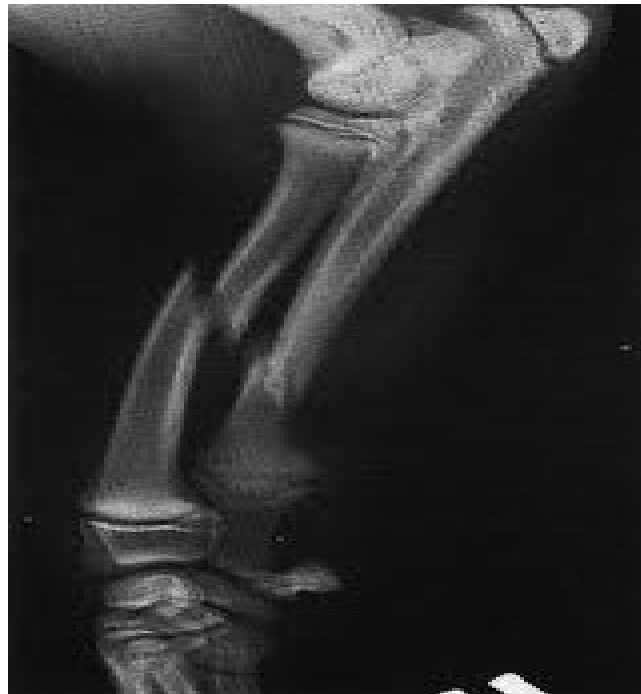It is a incomplete fracture in which the fracture lines runs along the longitudinal axis of the bone.



Cont...

Oblique Fracture:

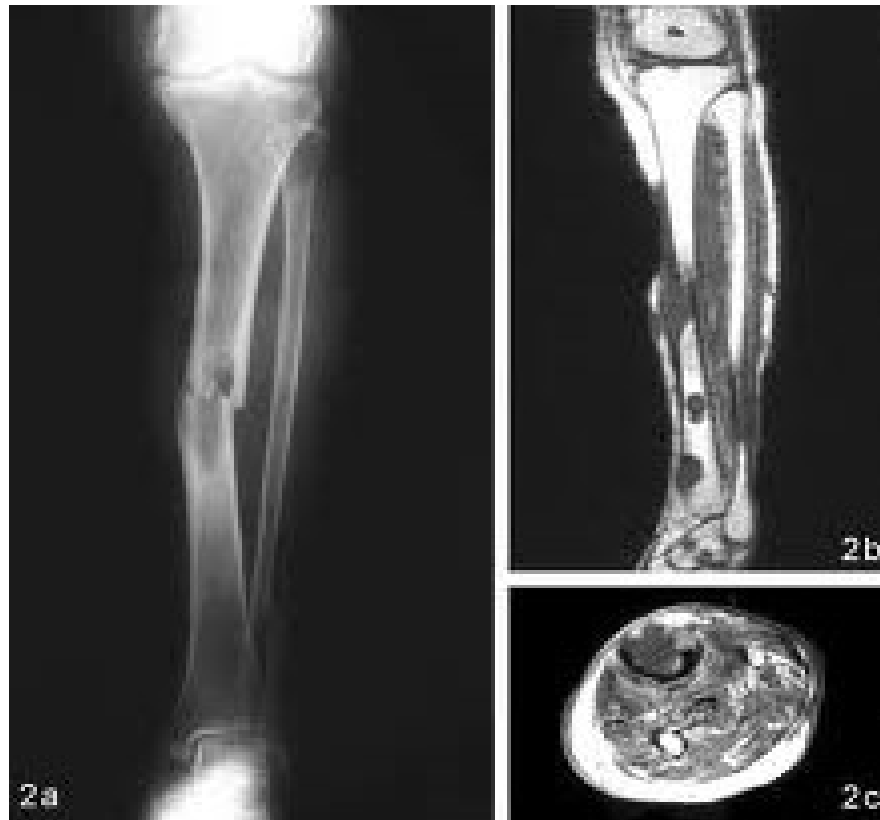It is a fracture in which the line of a fracture extends in a oblique direction



Cont...

Pathologic Fracture:

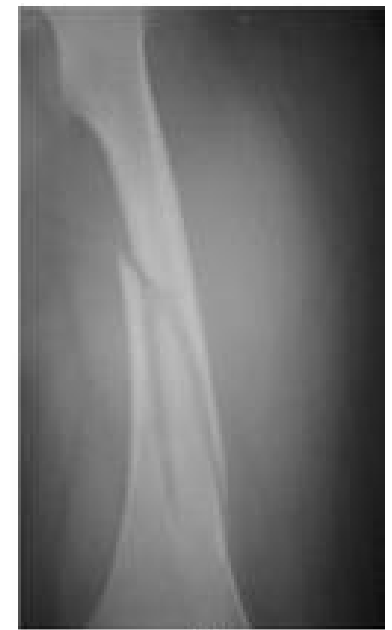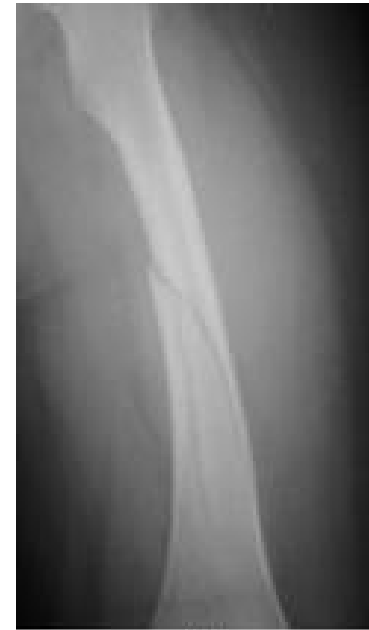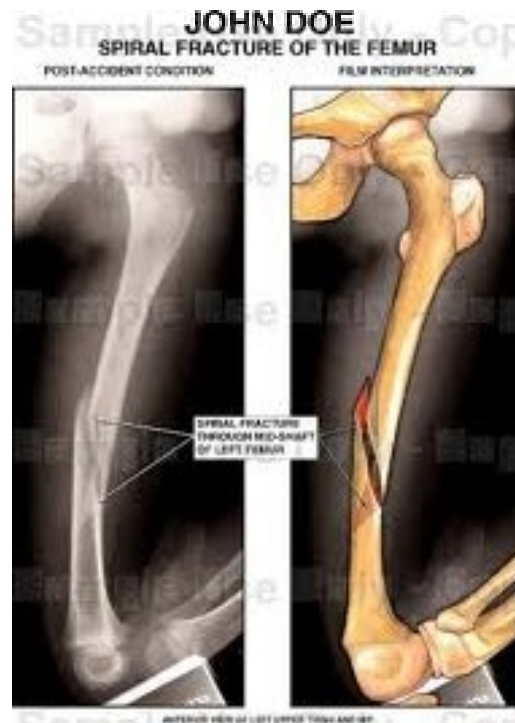it is a spontaneous fracture at the site of a bone diseases.



Cont...

Spiral Fracture:

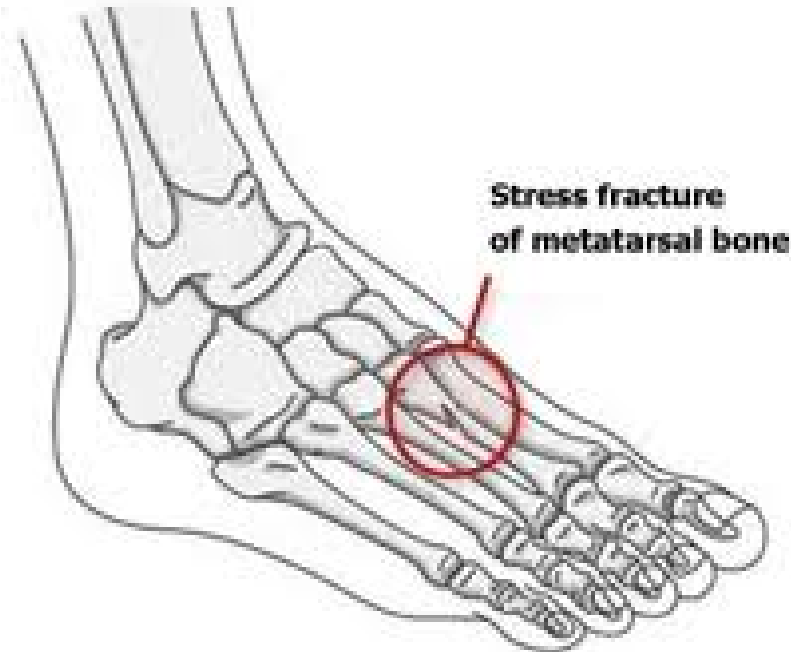
it is a fracture in which the line of fracture extends in the spiral direction along the direction of the bone.



Cont...

Stress Fracture:

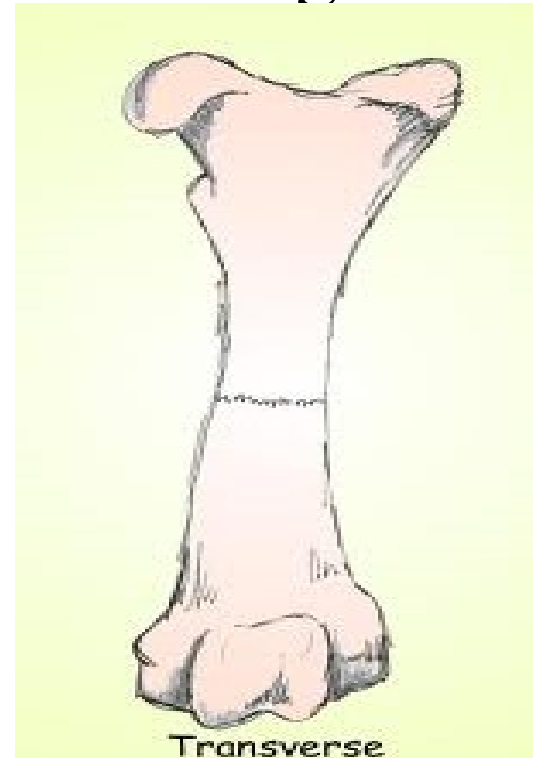
it is a fracture that occurs normal or abnormal bone that is subjected to repeated stress.



Cont...

Transverse Fracture:

it is a fracture in which the line of fracture extends across the bone shaft at the right way to longitudinal axis.



Others...

Stable Fracture:

Occurs when a piece of periosteum is intact across the fracture & other external or internal fixation has reduced the fragment

Unstable Fracture:

Is grossly displaced during injury and is a site of poor fixation

Clinical Manifestations

- Localized pain and tenderness
- Decreased function
- Inability to bear weight or use of the affected part
- Edema and Swelling
- Muscle Spasm
- Deformity

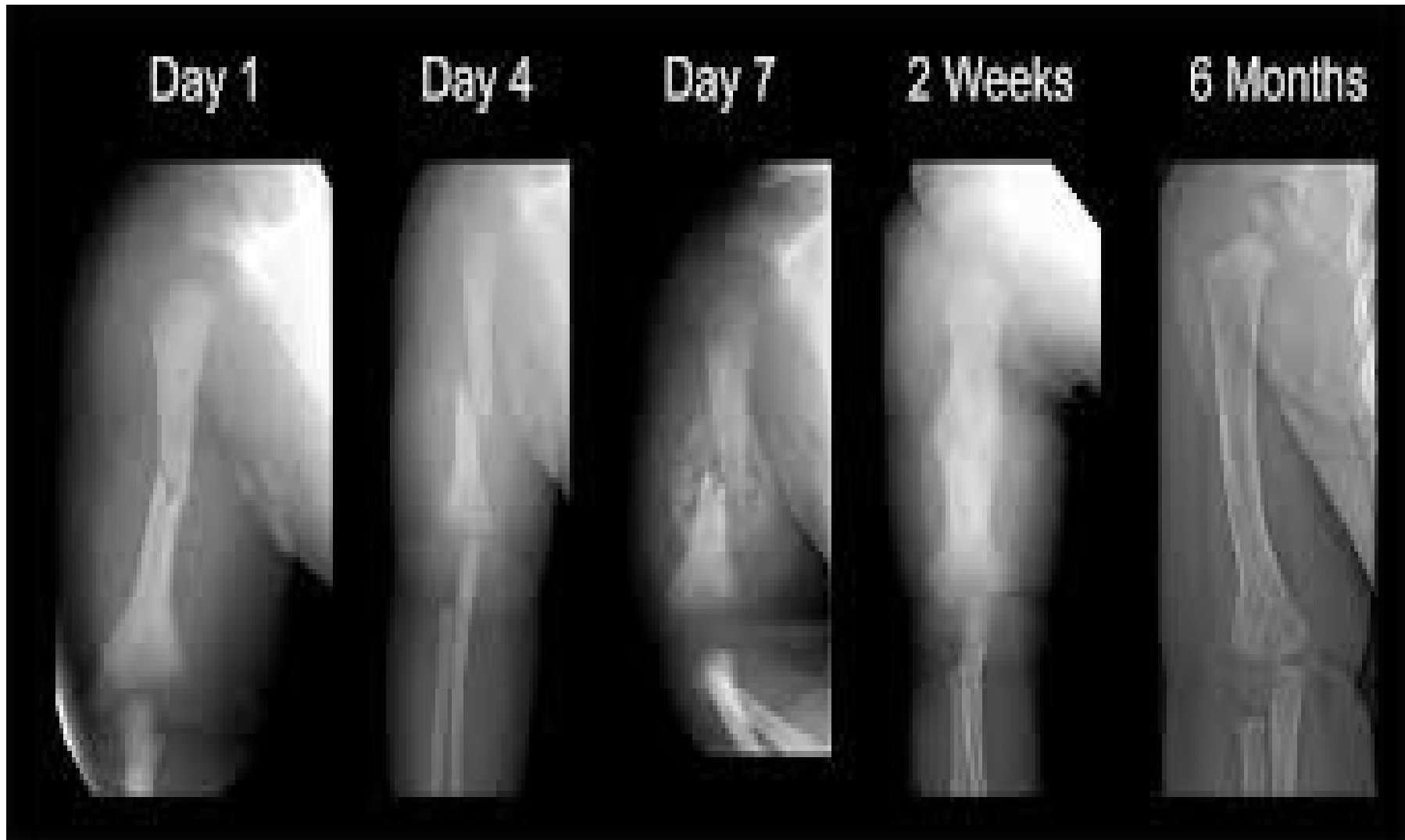Cont...

- Ecchymosis and Contusion
- Loss of function
- Crepitation

Fracture Healing Process

- Fracture Hematoma
- Granulation Tissue
- Callus Formation
- Ossification
- Consolidation
- Remodelling

Pics...



Cont...

Fracture Hematoma

when fracture occurs, bleeding creates a hematoma which surrounds the ends of fragments. Hematoma is extravasated blood that changes from a liquid to semisolid clot.

Occurs after 72 hrs of injury.

Cont...

Granulation Tissue

Active phagocytosis absorbs the products of local necrosis. The hematoma converts to granulation tissue. It produces the basis of new bone substances called osteoid

Cont...

Callus Formation

As minerals (Ca, P & Mg) and new bone matrix are deposited in the osteoid an unorganized network of bone is formed that is woven about the fractured parts.

Callus is primarily composed of cartilage osteoblasts, calcium and phosphorus. It usually appears at the end of second week after injury.

Cont...

Ossification

It occurs from 3 weeks to 6 months after the fracture and continues until fracture has healed.

It is sufficient to prevent movement at the fracture site.

at this stage patient may be allowed to limited mobility.

Cont...

Consolidation

As callus continues to develop the distance between bone fragments diminishes and eventually closes.

Cont...

Remodelling

Excess bone tissue is reabsorbed in the final stage of bone healing and union is completed. Gradual return of the injured bone to its pre injury structural strength and shape occurs.

DIAGNOSTIC EVALUATION

- History Collection
- Physical Examination
- X- Ray
- C.T. Scan
- MRI

COLLABORATIVE CARE

FRACTURE REDUCTION

Closed Reduction

Open Reduction

Traction

FRACTURE IMMOBILISATION

Splints and Casts

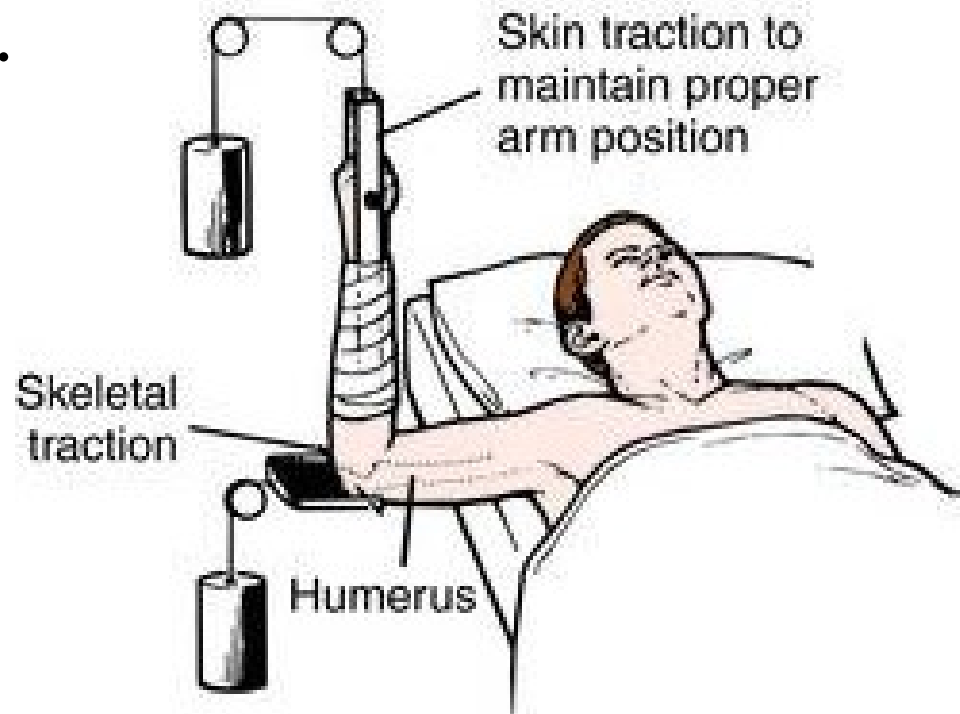
DRUG THERAPY

CLOSED REDUCTION

- It is a non surgical manual realignment of bone fragments to their previous anatomic position
- It is usually performed under local or general Anesthesia, After Reduction, traction, casting, external fixation splints are used to immobilize the injured part to maintain alignment

TRACTION

Is a application of pulling force to an injured or diseased part of the body or an extremity while counter traction pulls in the opposite direction.



Purpose

- To prevent / reduce muscle spasm
- Immobilizing a joint or part of the body
- Reduce fracture or dislocation
- Treat a pathologic joint condition

Indication

- Provide immobilization to prevent soft tissue damage
- Reduce muscle spasm associated with low back pain
- Expand a joint space during arthroscopic procedures
- Expand a joint space before major joint construction

TYPES

Skin Traction:

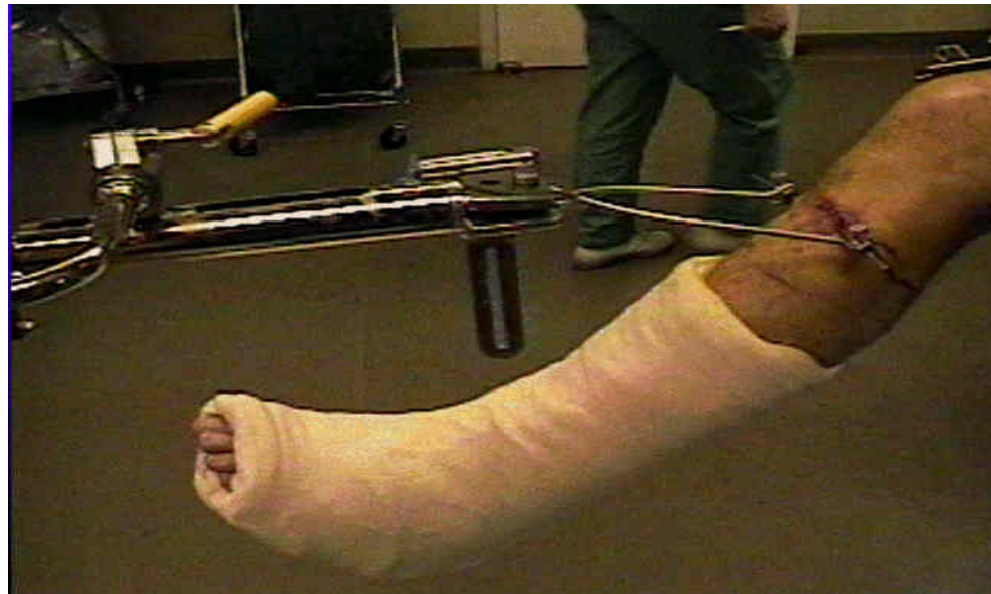
Used for short term treatment 48 – 72 hrs until skeletal traction or surgery is possible. The traction weights are usually limited to 05 to 10lb (2.3 to 4.5kg)



Cont...

Skeletal Traction

Skeletal traction is used for longer periods than skin traction, to align the injured bones and joints or to treat joint contractures and congenital hip dysplasia.

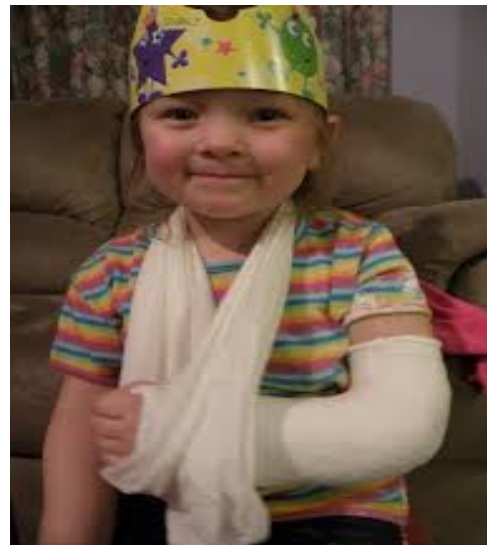

FRACTURE IMMOBILIZATION

CAST

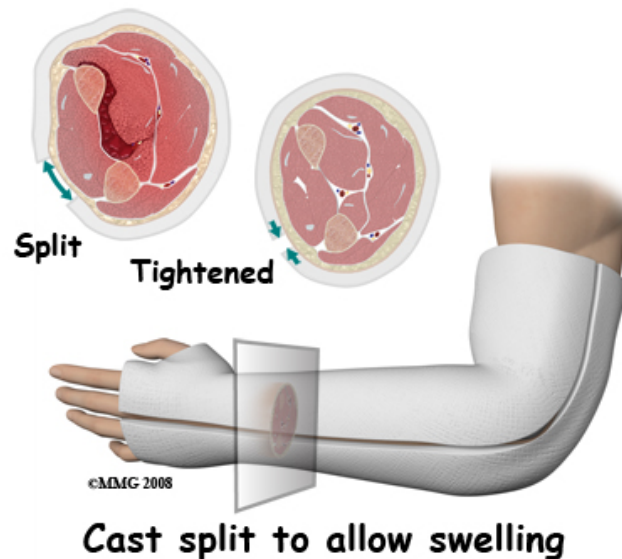
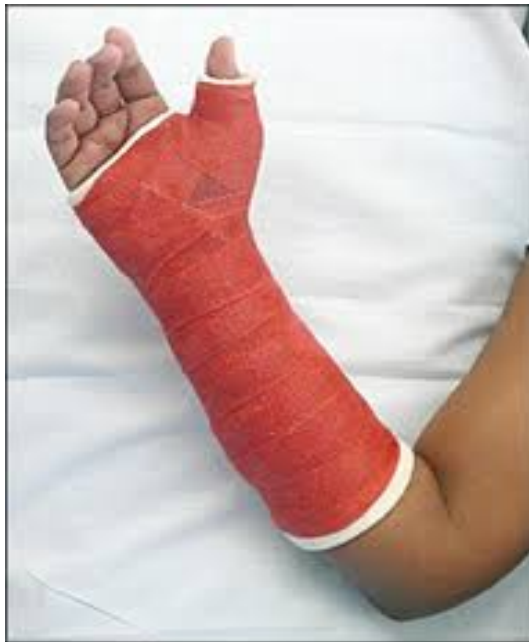A cast is a temporary circumferential immobilization device. It is a common treatment following closed reduction.

cast materials are natural (POP), synthetic, acrylic, fiber glass free.



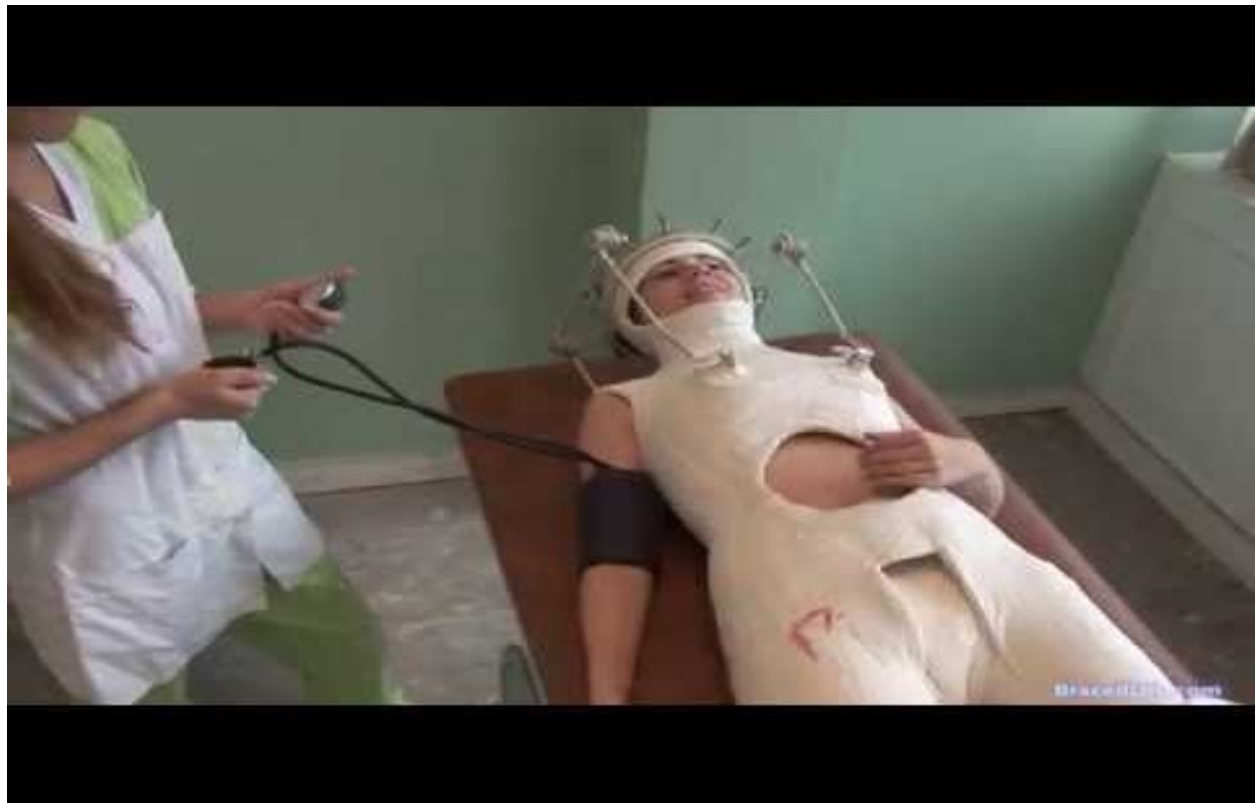TYPES

- **SHORT ARM CAST:** used for stabilizing wrist bones and meta carpels
- **LONG ARM CAST:** used for stable forearm or elbow fractures and unstable wrist fracture.



Cont...


BODY JACKET CAST: used for immobilization and support for stable spine injury of the thoracic or lumbar spine



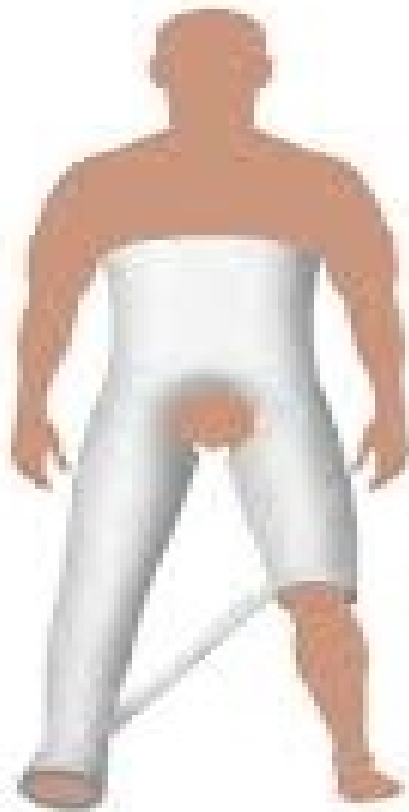
Cont...

- HIP SPICA CAST: is used for treatment of femoral fractures. It includes two casts Body Jacket Cast and Long Leg Cast
- For Lower Extremities
 - SHORT LEG CAST
 - LONG LEG CAST

Cont...



Unilateral Hip
Spica Cast



One and One-half
Hip Spica Cast



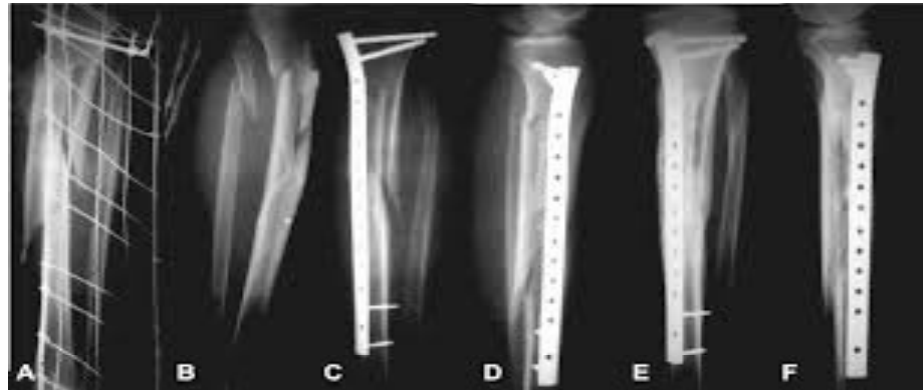Bilateral Long-leg
Hip Spica Cast

OPEN REDUCTION

- It is the correction of bone alignment through a surgical incision. It usually includes internal fixation of the fracture with the use of wires, screws, pins, plates, intramedullary rods or nails.

TYPES

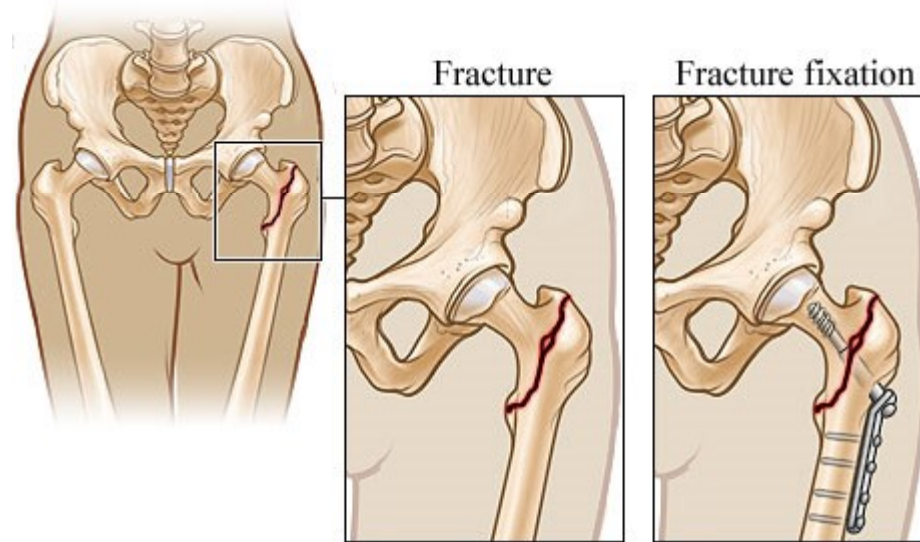
- Open Reduction Internal Fixation



- Closed Reduction External Fixation



Pic..



Pics....

Plates



Pics...

Screws



1.5 MM CORTICAL SCREW

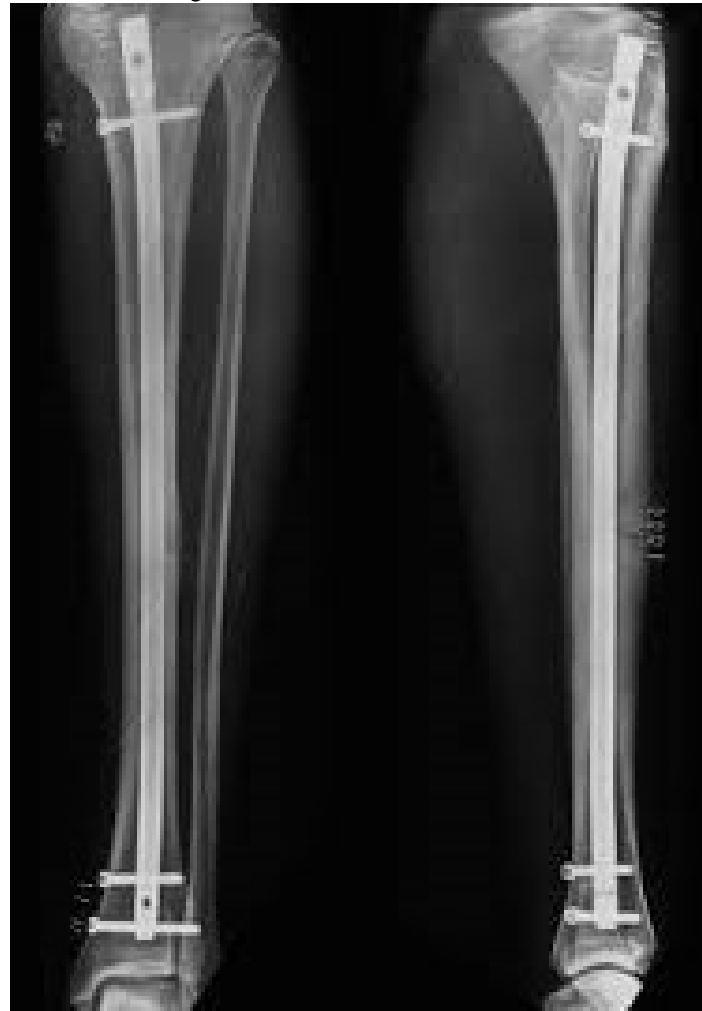

2.0 MM CORTICAL SCREW

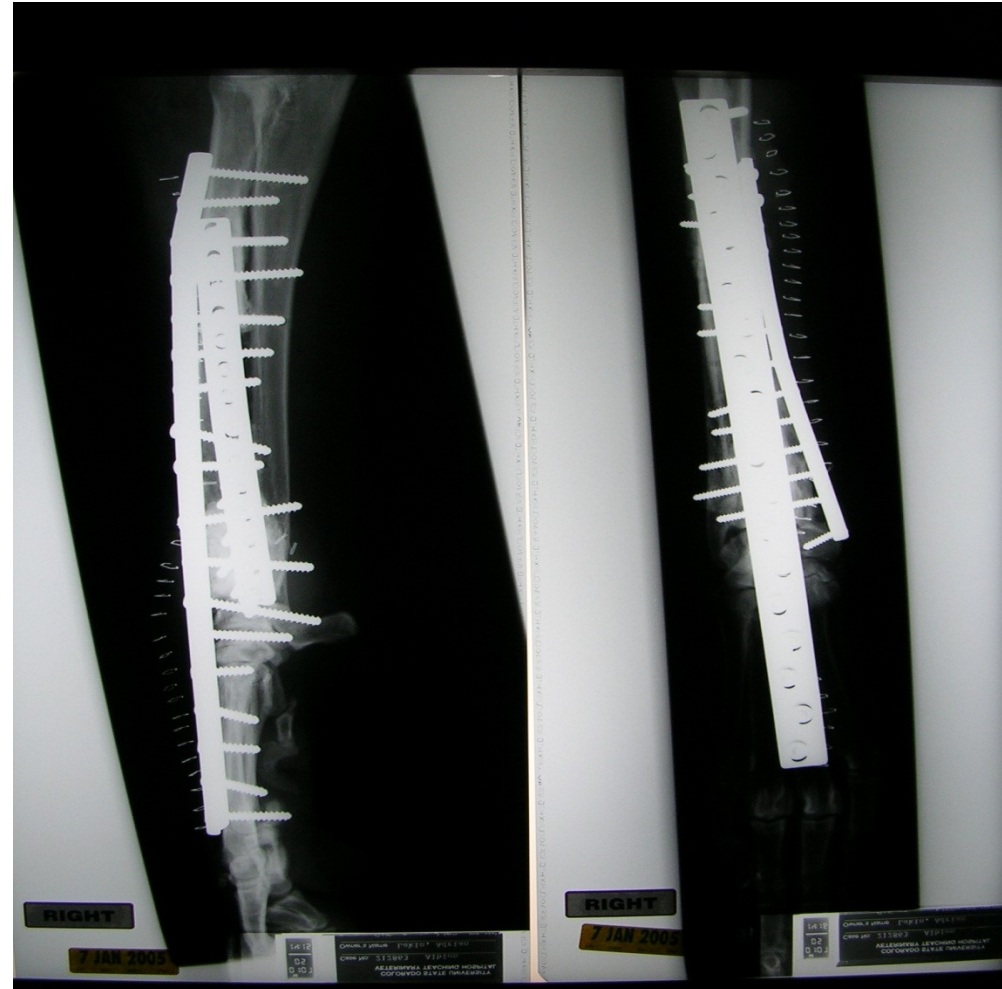
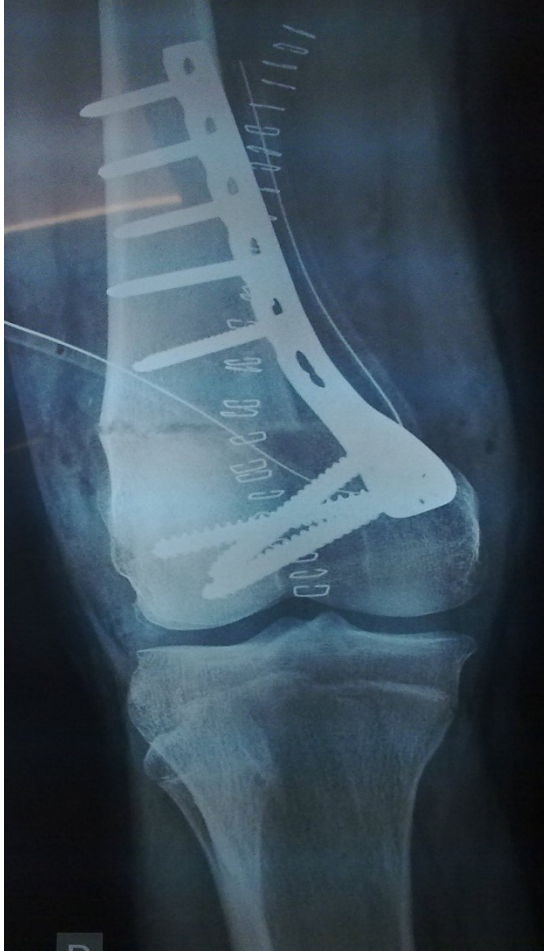

Pics...

- Intra medullary Nails



Pics...



DRUG THERAPY

- Antibiotics
- Muscle Relaxants
- Analgesics
- Inj. TT

Emergency Management

- Treat life threatening injuries first
- Ensure A, B and C
- Control external Bleeding with direct pressure
- Splint joints above and below fracture site
- Check Neurovascular Status distal to injury
- Elevate injured limb if possible
- Do not attempt to straighten fracture

Cont...

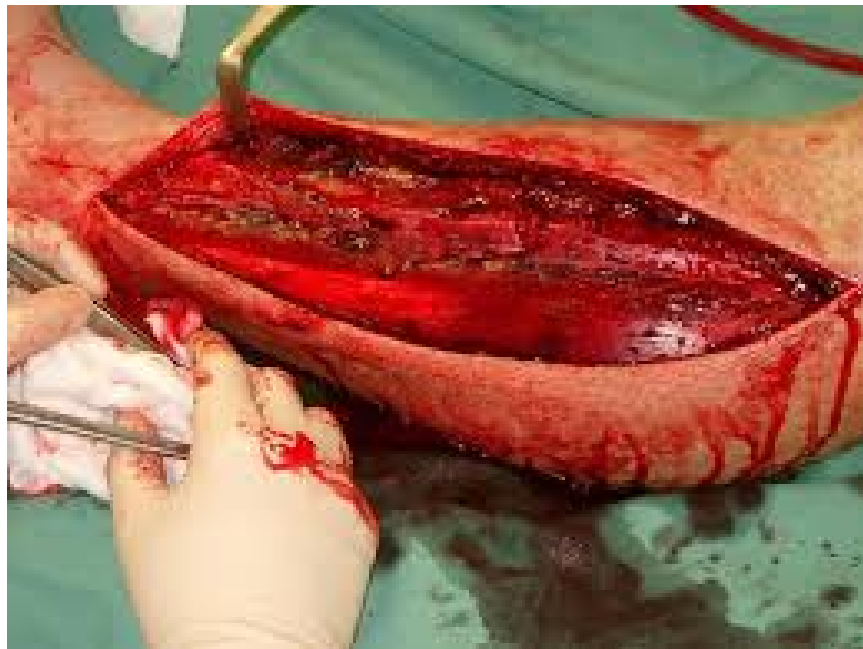- Do not manipulate protruding bone ends
- Apply ice packs to affected area
- Obtain X-rays of affected part
- Administer TT prophylaxis
- Shift immediately to health care centre

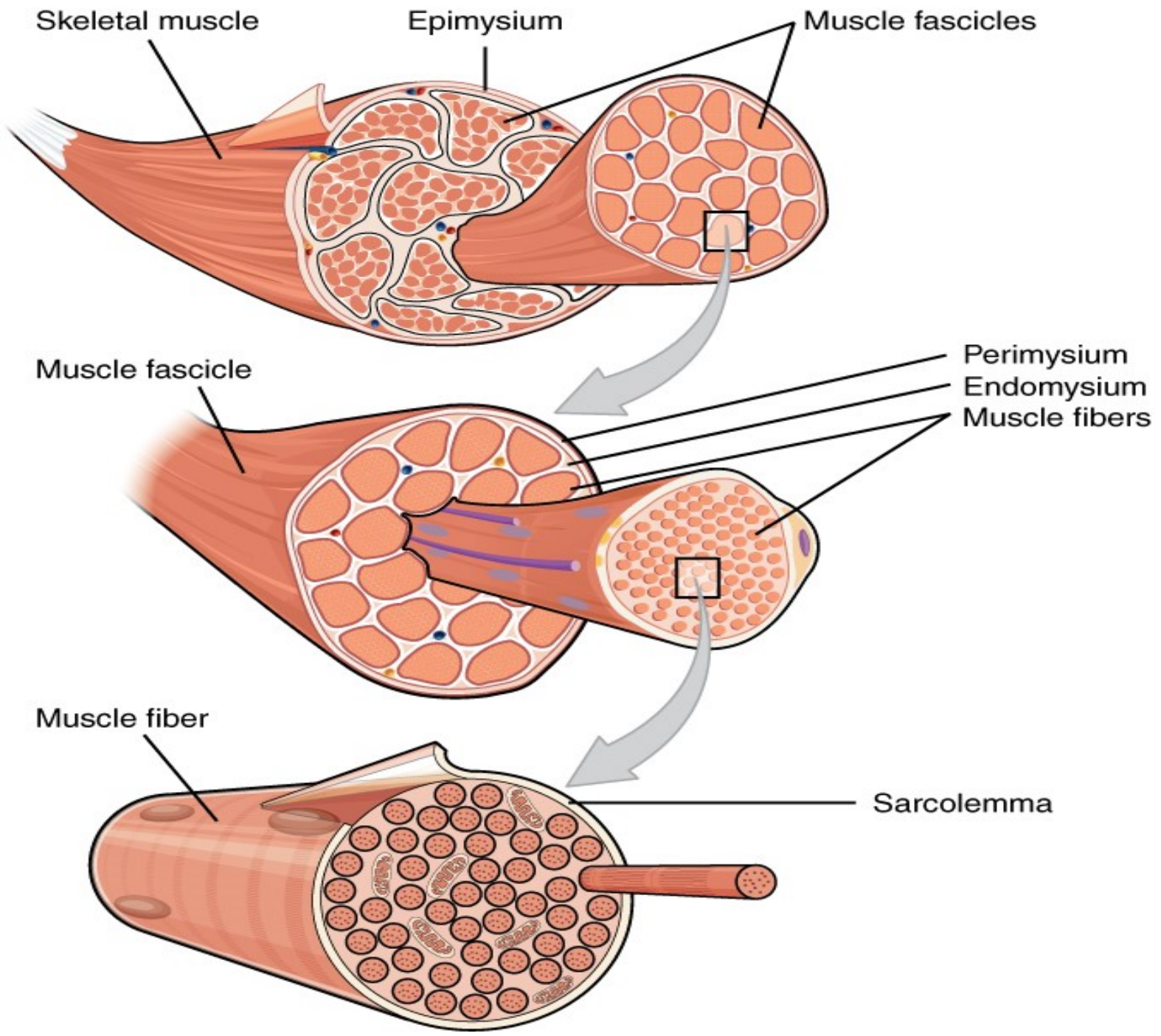
Complications

- Infection
- Compartmental Syndrome
- Venous Thrombosis
- Fat Embolism Syndrome

Compartmental Syndrome

It is a condition in which elevated intra compartmental pressure within a confined myofascial compartment compromises the neurovascular function of tissue within the space.





Types

- Decreased compartment size resulting from restrictive dressing.
- Increased compartment size related to bleeding or odema

Clinical Manifestations

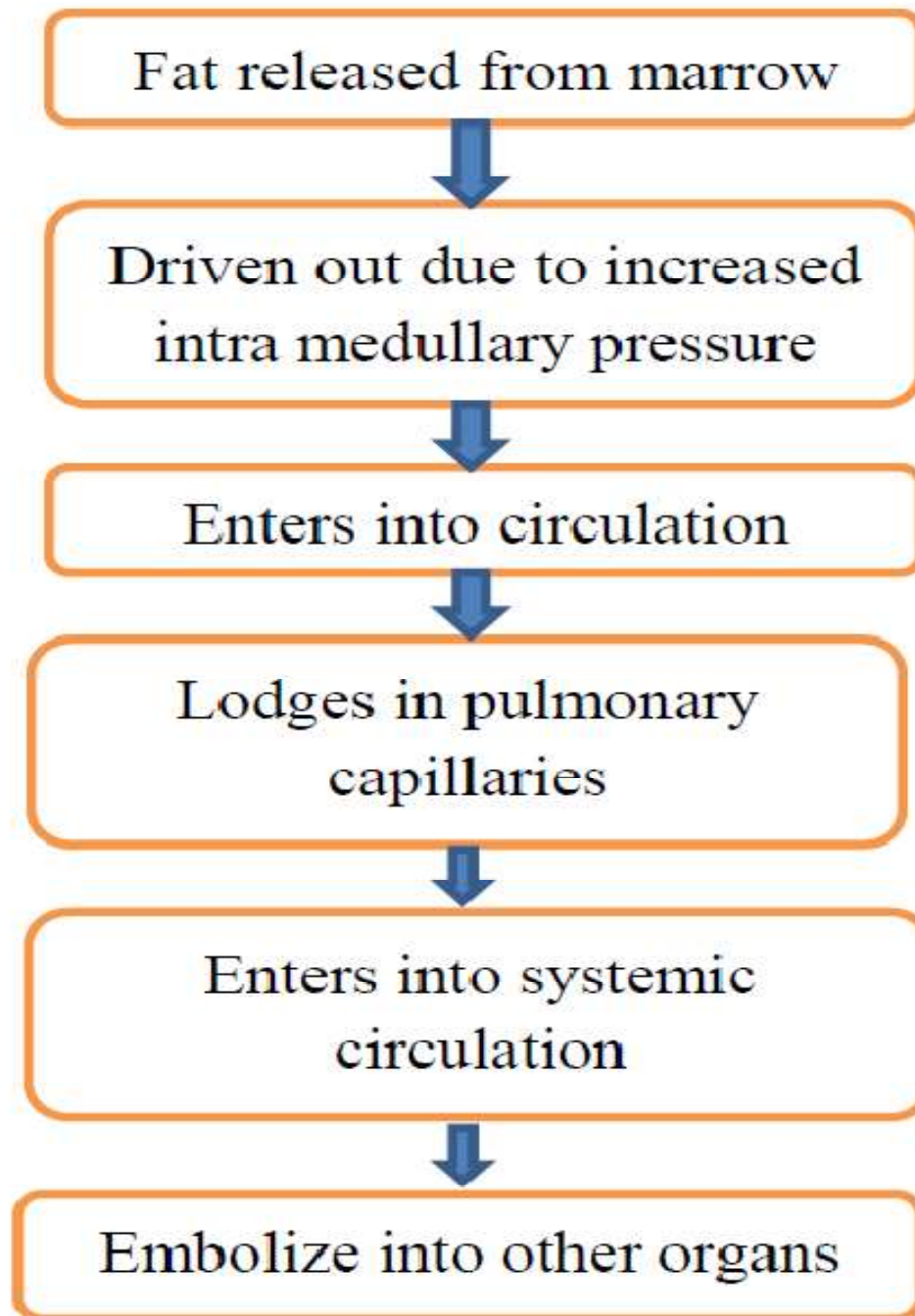
- Parasthesia
- Pain distal to injury
- Pressure increased
- Pallor, coolness
- Paralysis
- Pulselessness
- Myoglobinuria (brown Color)

Care

- Elevate body part above chest level
- Remove or loosen tight bandage
- Surgical decompression - Fasciotomy

Fat Embolism Syndrome

It is characterized by the presence of systemic fat globules from fractures that are distributed into tissues and organs after a traumatic skeletal injury



Clinical Manifestations

- Usually occurs 12 to 72 hrs. after injury
- Chest pain
- Tachypnea
- Cyanosis
- Tachycardia
- Memory loss
- Restlessness
- Confusion and Head ache

Diagnostic Evaluation

- Fat cells in blood, urine or sputum
- PaO₂ less than 60 mm Hg
- ST segment changes

Treatment

- Careful immobilization
- Fluid Resuscitation to prevent Shock
- Correction of Acidosis
- Corticosteroids
- Oxygen Administration