



RAMA
UNIVERSITY

www.ramauniversity.ac.in

FACULTY OF NURSING



RAMA UNIVERSITY

OSTEOMYELITIS

Mr. M.Raghavendran M.Sc(N)
Professor
MSN Dept

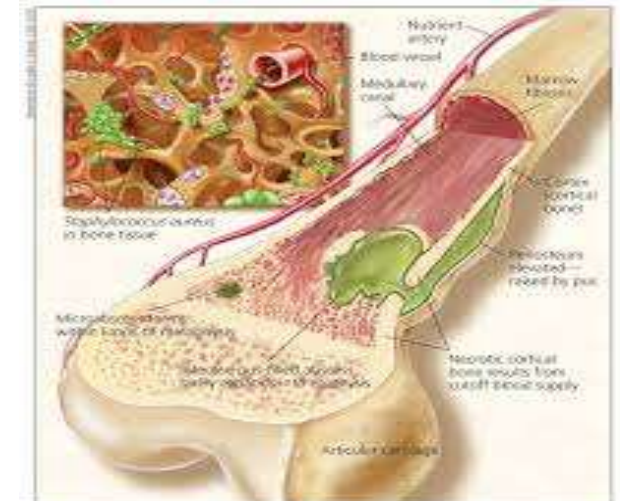


Figure 1 - This diagram shows hyperosteous osteomyelitis of a tubular bone in a child.

OSTEOMYELITIS

- It is a severe infection of the bone, bone marrow and surrounding soft tissue. The most common infecting microorganism is staphylococcus Aureus, other organisms include E.Coli, Salmonella, N. Gonorrhoea, Pseudomonas aeruginosa.

Cont...


- The infecting microorganism can invade by direct or indirect entry. Direct entry is occur at any age when there is an open wound and microorganism gain entry into the body. Indirect entry (hematogenous) of microorganisms most frequently affects growing bone in boys less than 12 years of age.
- The most common sites of entry are distal femur, proximal tibia, humerus and radius

Pathophysiology

Microorganisms enter into the body



Lodging in an area of bone results in reduced blood circulation



Microorganisms grow inside bone



Pressure increases inside bone due to its nonexpanding nature

Cont....

Ischemia and vascular compromise

```
graph TD; A[Ischemia and vascular compromise] --> B[Infection passes through bone cortex and marrow cavity]; B --> C[Cortical devascularisation and necrosis]; C --> D[Death bone formation (Sequestrum)];
```

Infection passes through bone cortex and marrow cavity

Cortical devascularisation and necrosis

Death bone formation (Sequestrum)

Cont...

Sequestrum continues to be an infected island



Surrounded by pus and difficult to reach by blood borne antibiotics

Clinical Manifestations

- Acute: less than 1 month

Systemic Manifestations: fever, chills, night sweats, restlessness, nausea & malaise

Local Manifestations: Bone pain, relieved by rest and worsens by activity, swelling, tenderness and warmth at infection site, restricted movement.

Cont...

- Chronic: more than 1 month

Systemic signs diminished and local signs are more common including bone pain, swelling, tenderness and warmth.

Diagnostic Evaluation

Bone or soft tissue biopsy, blood or wound culture, increased WBC & ESR, MRI, CT Scan, Radio nucleotide bone scans (Gallium and Indium).

Management

Vigorous and prolonged IV antibiotic therapy is advised and if it is delayed, surgical debridement and compression are necessary.

IV antibiotic therapy for 4 – 6 weeks or as long as 3 – 6 months, Drugs include penicillin, neomycin, cephalixin, cefazolin, gentamycin and tobramycin

Cont...

- Surgical treatment for chronic osteomyelitis includes removal of the poorly vascularized tissue and dead bone.