



RAMA  
UNIVERSITY

[www.ramauniversity.ac.in](http://www.ramauniversity.ac.in)

FACULTY OF NURSING

# CHOLELITHIASIS



BY:-

Kalpana Devi

Nursing Tutor

MSN Department

Rama College Of Nursing

# DEFINITION

- The presence of stones in the gallbladder is referred to as cholelithiasis, from the Greek *chol-* (bile) + *lith-* (stone) + *-iasis* (process).
- If gallstones migrate into the ducts of the biliary tract, the condition is referred to as choledocholithiasis
- form from the solid constituents of the bile; they may vary greatly in size, shape, & composition.
- Uncommon in children & young adults but become more prevalent with increasing age.

# INCIDENCE & PREVALENCE

- 2% in south-7 % in north.
- ↑ in women, especially multiparous women & person
- ↑ 40 yr of age.

# RISK FACTORS

- Women
- Mutiparity
- Birth control pills
- Pregnancy
- A family history
- Obesity
- Diabetes
- Sedentary life style
- Liver disease
- Rapid weight loss.

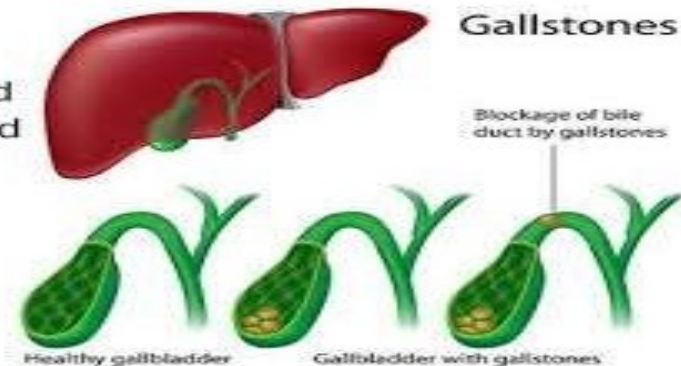
## PREDISPOSING FACTOR OF CHOLELITHIASIS (AKA GALLSTONES)

### 4 F's

- **F**at
- **F**orty
- **F**emale
- **F**ertile



Cholelithiasis is the formation of stones in your gallbladder, also called gallstones. Your gallbladder is located on the right side of abdomen near your liver. Your gallbladder stores bile, which helps break down the fat that you eat.

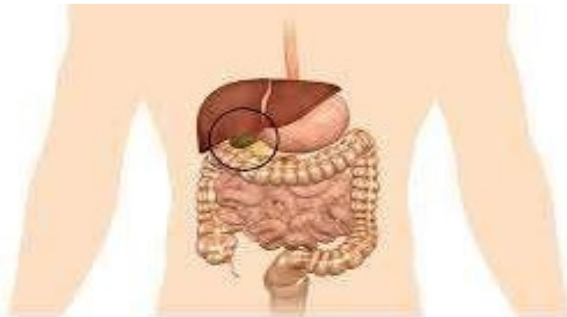

# TYPES OF GALLSTONES

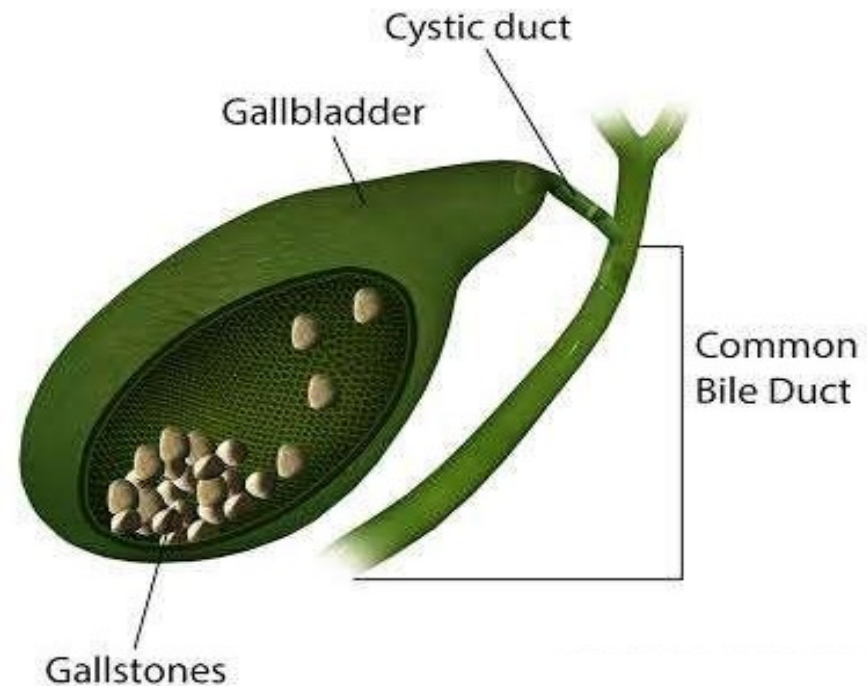
- There are three types of gall stone-

## Types of Gallstones

- Cholesterol Stones
- Pigment Stones
- Mixed Stones



## Gallstones



# CHOLESTEROL STONES

- Composed mainly of cholesterol (> 50% of stone composition) & comprises multiple layers of cholesterol & mucin glycoproteins.
- Pure cholesterol stones are not common; they comprise less than 10% of all stones.
- Most other cholesterol stones contain variable amounts of bile pigments & calcium.



- If excessive cholesterol or insufficient bile acids are secreted, bile becomes supersaturated with cholesterol which then precipitates out as cholesterol crystals & stones.
- The incidence increase with age, & the prevalence higher in women. Stones are usually smooth & whitish yellow to tan.

# PIGMENT STONES

- It probably form when unconjugated pigments in the bile precipitate to form stone.
- In these people bile contains an excess of unconjugated bilirubin.

- Pigment stones are dark due to the presence of calcium bilirubinate & are usually formed secondary to hemolytic disorders such as sickle cell disease & spherocytosis, & in those with cirrhosis. Two types are recognized, black & brown.
- Pigment stones cannot be dissolved & must be removed surgically

# Black pigment stones

- Most common
- Formed in gall bladder
- Common in hemolytic disorders, cirrhosis
- Multiple , small & hard in consistence.
- bilirubinate, phosphate, bicarbonate, calcium.

## Brown stones-

- Rare
- Formed in bile duct usually after bacterial infection caused by bile stasis.
- The bacteria responsible for the infection enzymatically catalyze the conversion of bilirubin glucuronide to insoluble unconjugated bilirubin
- Major constituents are precipitated calcium bilirubinate & bacterial cell bodies.

# MIXED STONES

- Most common type.
- It may be combination of cholesterol & pigment stones or either of these with some other substances.
- Calcium carbonate, phosphate, bile salts, & palmitate make up more common minor constituents.

# PATHOPHYSIOLOGY

Decreased bile acid synthesis



Increased cholesterol synthesis in the liver



Super saturation of bile with cholesterol



Formation of precipitates



Gall stones (Cholelithiasis)



Inflammatory changes (Cholecystitis)



# CLINICAL MANIFESTATIONS

May develop two types of symptoms:

- Due to disease of the gallbladder itself
- Due to obstruction of the bile passages by a gallstone.
- May be acute or chronic.
- Epigastric distress, such as fullness, abdominal distention & vague pain in the right upper quadrant.
- May follow a meal rich in fried or fatty foods.

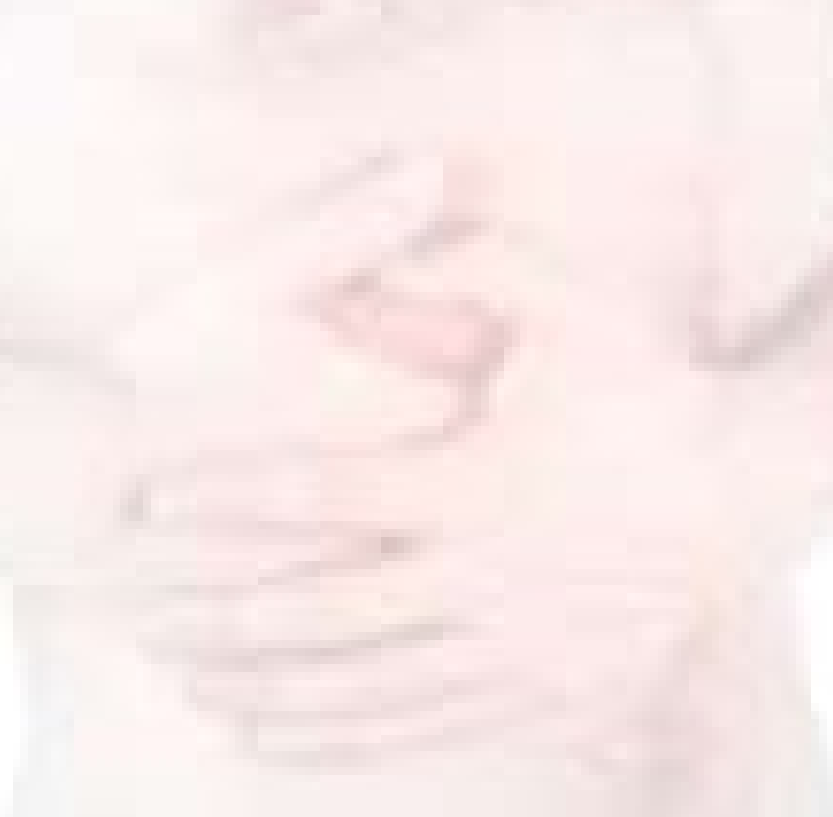

# PAIN & BILIARY COLIC

- Gallstone obstructs the cystic duct, becomes distended, inflamed & eventually infected (acute cholecystitis).
- Develops a fever & may have a palpable abdominal mass.
- May have biliary colic with excruciating upper right abdominal pain that radiates to the back or right shoulder, is usually associated with nausea & vomiting & is noticeable several hours after a heavy meal.

- Moves about restlessly, unable to find a comfortable position ,the pain is constant rather than colicky.
- Such a bout of biliary colic is caused by contraction of the gallbladder, which cannot release bile because of obstruction by the stone.
- When distended, the fundus of the gallbladder comes in contact with the abdominal wall in the region of the right ninth & tenth costal cartilages.
- Produces marked tenderness in the right upper quadrant on deep inspiration & prevents full inspiratory excursion.

- If dislodged & no longer obstructs the cystic duct, the gallbladder drains & the inflammatory process subsides after a relatively short time.
- If continues to obstruct the duct, abscess, necrosis & perforation with generalized peritonitis may result.



# JAUNDICE

- Occurs in a few patients & usually occurs with obstruction of the CBD.
- The bile, which is no longer carried to the duodenum, is absorbed by the blood & gives the skin & mucous membrane a yellow color.
- frequently accompanied by marked itching of the skin.

# CHANGES IN URINE & STOOL COLOR

- The excretion of the bile pigments by the kidneys gives the urine a very dark color.
- The feces, no longer colored with bile pigments, are grayish, like putty, & usually described as clay-colored.

# VITAMIN DEFICIENCY

- Obstruction of bile flow also interferes with absorption of the fat soluble vitamins A, D, E, & K.
- May exhibit deficiencies of these vitamins.
- If biliary obstruction has been prolonged (eg, bleeding caused by vitamin K deficiency, which interferes with normal blood clotting)

# ASSESSMENT & DIAGNOSTIC FINDINGS

- Abdominal ultrasound
- Ultrasonography
- Radionuclide imaging or cholescintigraphy
- Cholecystography
- Endoscopic retrograde cholangiopancreatography
- Percutaneous transhepatic cholangiography

# ABDOMINAL ULTRASOUND

- If gall bladder stone is suspected, an abdominal x- ray may be obtained to exclude other causes of symptoms. However, only 10 to 15% gall stone are calcified sufficiently to be visible on such x - ray studies.



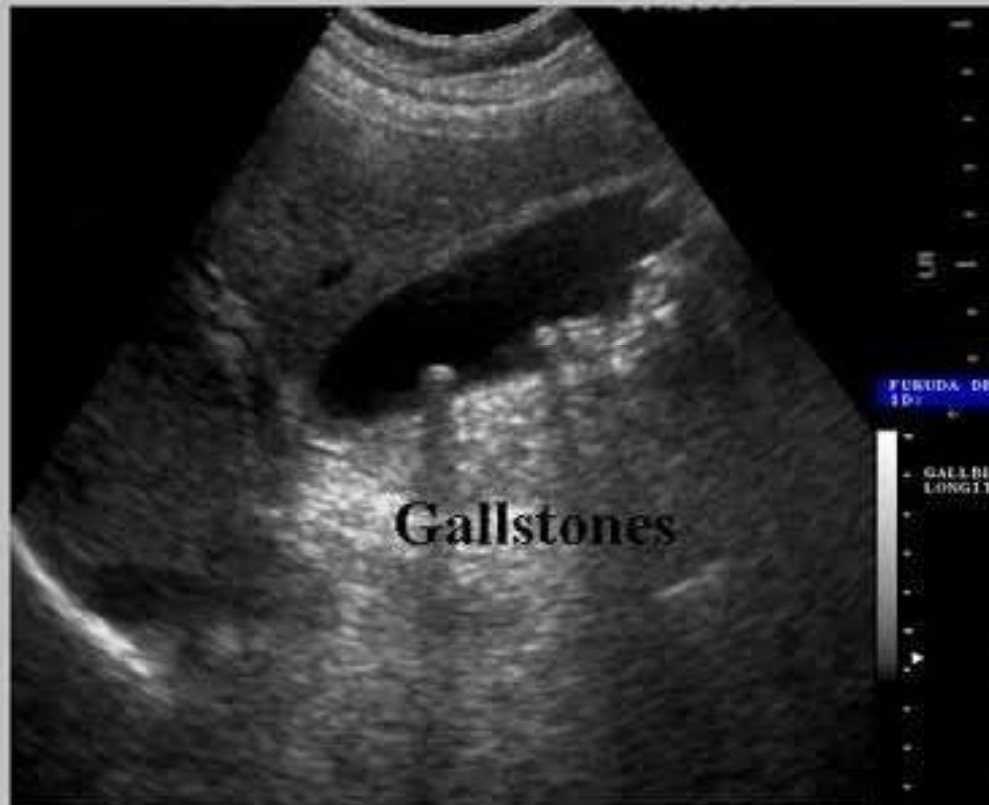# ULTRA SONOGRAPHY

- Replaced cholecystography as the diagnostic procedure of choice
- Does not expose patients to ionizing radiation.
- Most accurate if the patients fasts overnight so that the gall bladder is distended.
- Detect calculi in the gall bladder or a dilated common bile duct with 90% accuracy.
- Obesity, ascites & distended bowel may be difficult to examine satisfactorily with an ultrasound.

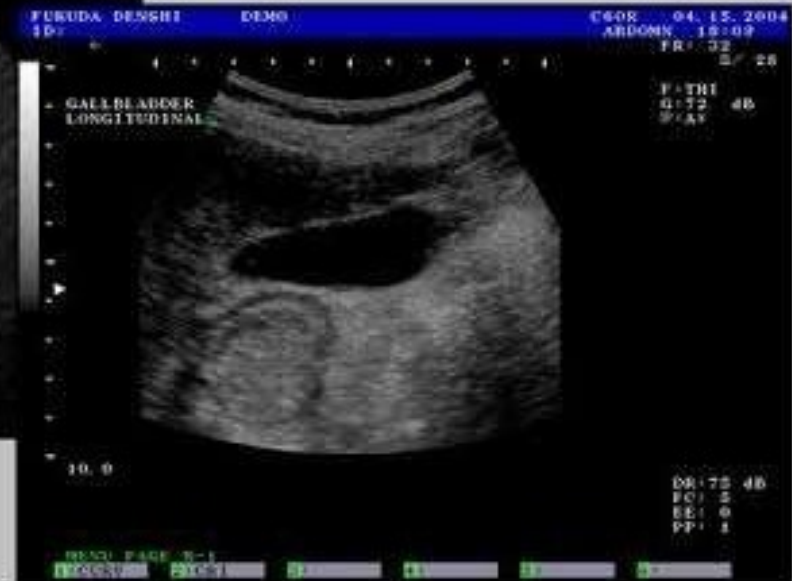- Stones are acoustically dense & produce an acoustic shadow. Stones also move with changes in position.
- Polyps may be calcified & reflect shadows, but do not move with change in posture.
- Thickened gallbladder wall & local tenderness indicate cholecystitis.
- When a stone obstructs the neck of the gallbladder, the gallbladder may become very large, but thin walled.
- A contracted, thick-walled gallbladder indicates chronic cholecystitis .

# ***Cholelithiasis***

Ultrasound



Ultrasound image obtained with a 3,5-MHz transducer demonstrates the multiple stones in the gallbladder with typical **acoustic shadows**.



# RADIONUCLIDE IMAGING CHOLESCINTIGRAPHY

- used successfully in the diagnosis of acute cholecystitis or blockage of a bile duct.
- Radioactive agent is administered IV
- Taken up by the hepatocytes & excreted rapidly through the biliary tract.
- Then scanned & image of the gall bladder & biliary tract are obtained.

- More expensive than USG
- Takes longer to perform
- Expose the patient to radiation
- Often used when ultrasonography is not conclusive such as acalculous cholecystitis.

# CHOLECYSTOGRAPHY

- Has been replaced by ultrasonography as the test of choice
- Oral cholangiography may be performed to detect gallstones & to assess the ability of the gallbladder to fill, concentrate its contents, contract & empty.
- Iodide-containing contrast agent excreted by the liver & concentrated in the gallbladder is administered to the patient.
- Normal gallbladder fills with this radiopaque substance.
- Appear as shadows on the x-ray film.

- Contrast agents include iopanoic acid (Telepaque), iodipamide meglumine (Cholografin) & sodium ipodate (Oragrafin).
- Administered orally 10 to 12 hours before the x-ray study.
- To prevent contraction & emptying of the gallbladder, the patient is NPO after the contrast agent is administered.
- Asked about allergies to iodine or seafood.
- An x-ray of the right upper abdomen is obtained.
- If the gallbladder is found to fill & empty normally & to contain no stones, gallbladder disease is ruled out.

# CHOLECYSTOGRAPHY

Visualize the gallbladder by administering a radiopaque contrast agent (by mouth) that is excreted by the liver. This excreted material will collect in the gallbladder where reabsorption of water concentrates the excreted contrast.

vesica felea →  
fundus →  
the last rib →  
air in intestinum →  
os coxae →

Th 12

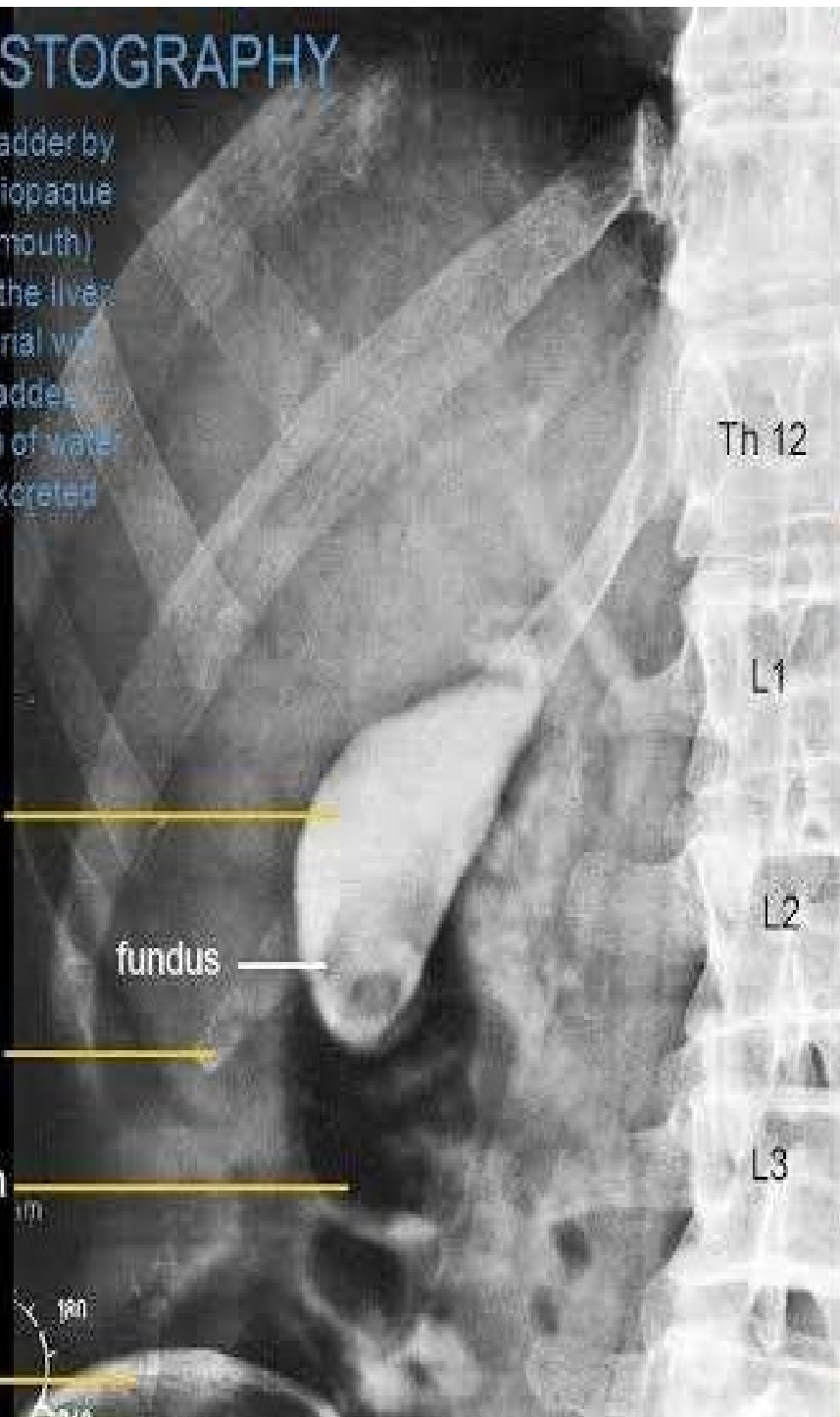L1

L2

L3

thoracic  
vertebrae

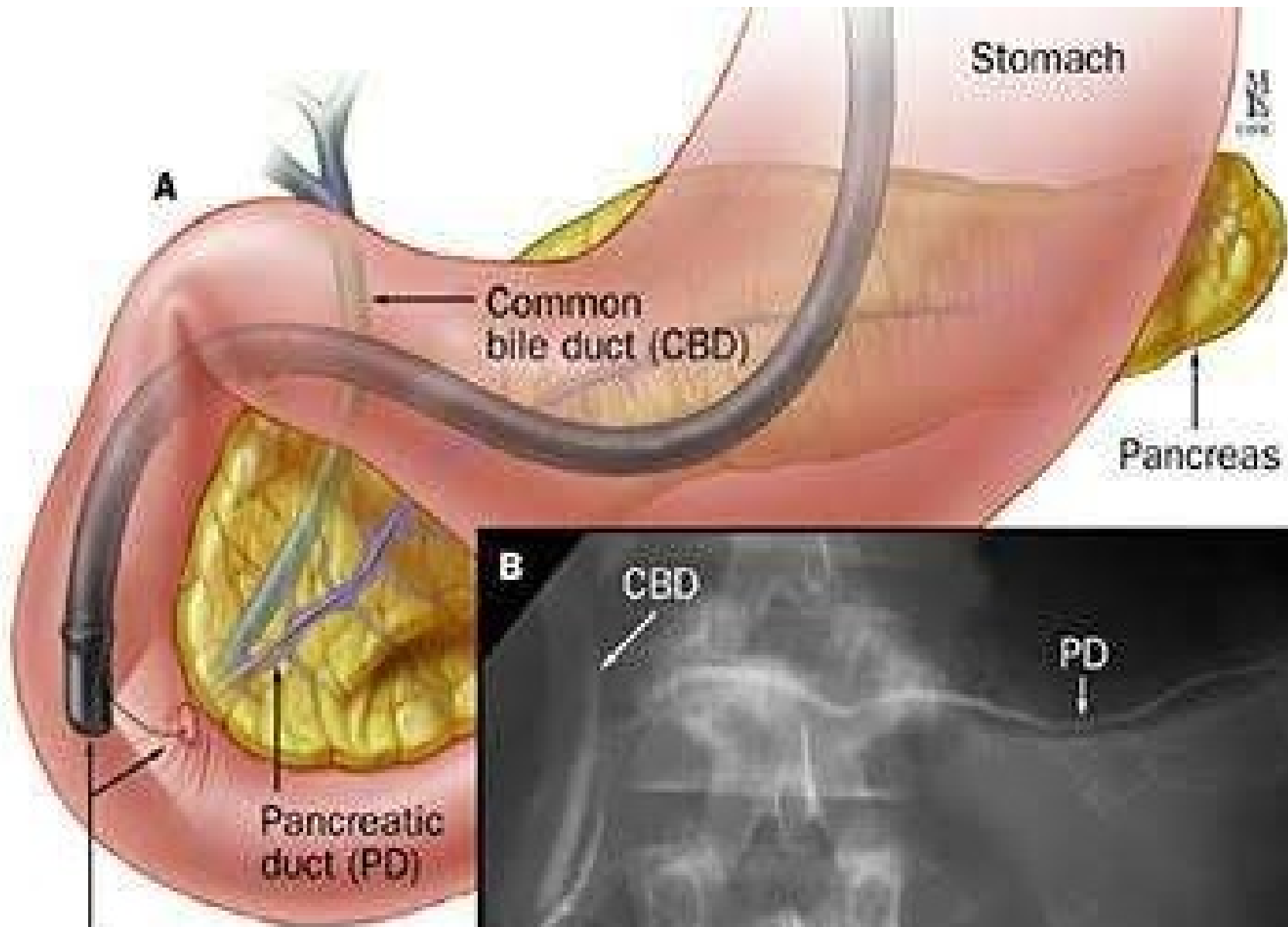
lumbar  
vertebrae



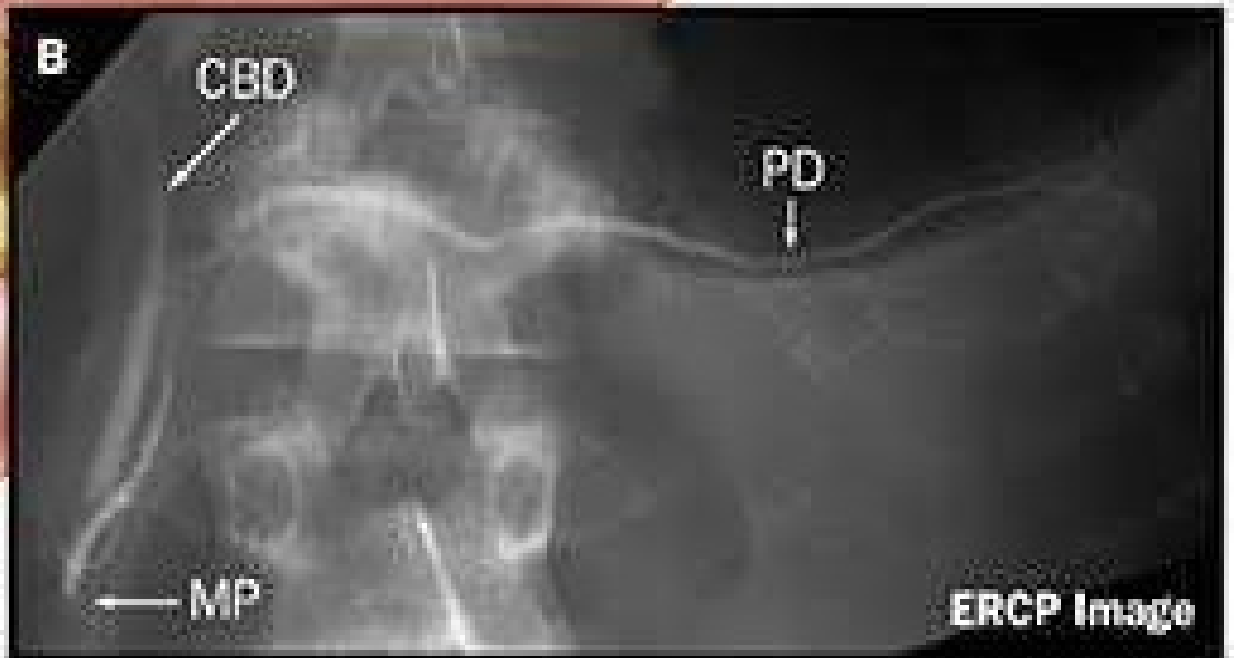

# ENDOSCOPIC RETROGRADE CHOLANGIOPANCREATOGRAPHY

- Permits direct visualization of structures that could once be seen only during laparotomy.
- Examination of the hepatobiliary system is carried out via a side-viewing flexible fiberoptic endoscope inserted into the esophagus to the descending duodenum.
- Multiple position changes are required during the procedure, beginning in the left semiprone position to pass the endoscope.
- Fluoroscopy & multiple x-rays are used.



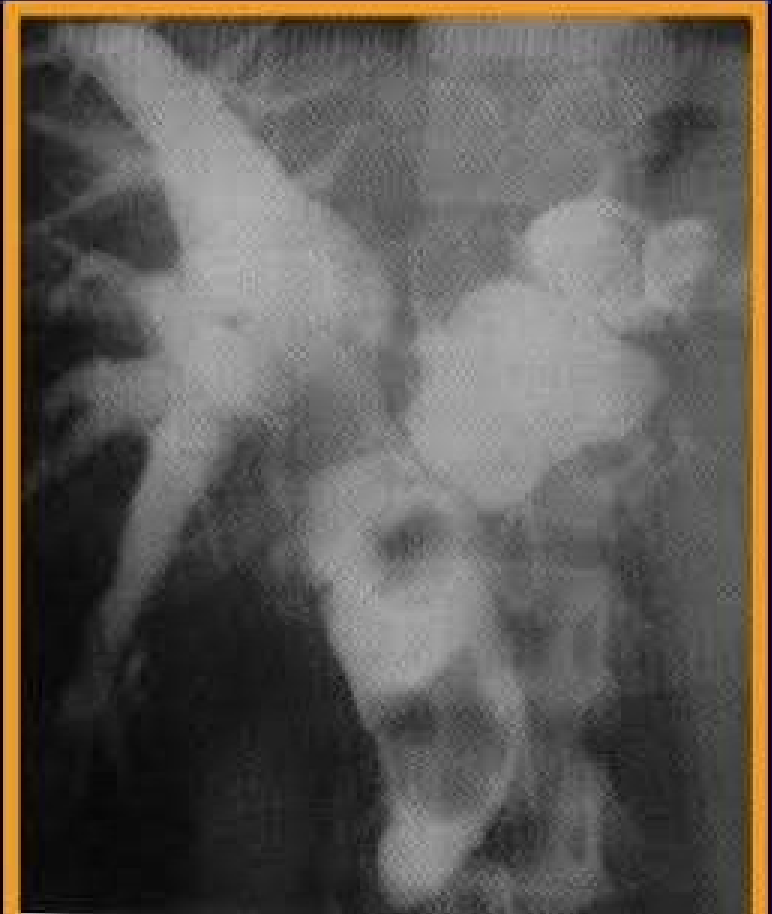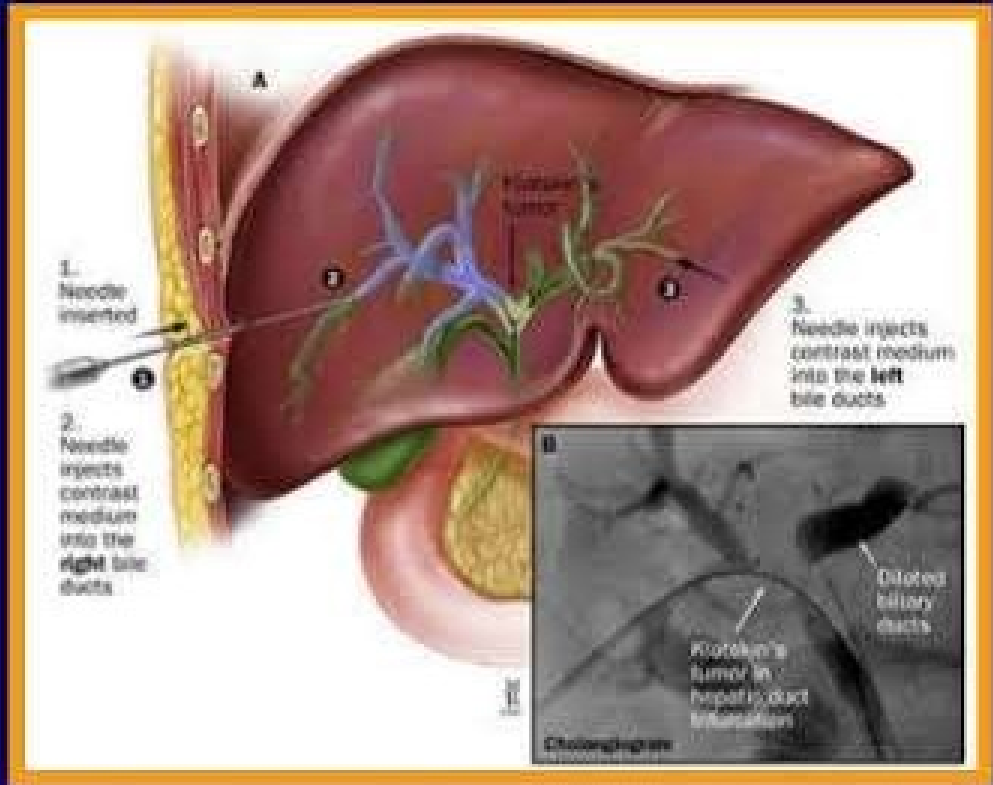
Endoscope viewing major papilla (MP) in duodenum (blue = contrast medium)



# PERCUTANEOUS TRANSHEPATIC CHOLANGIOGRAPHY

- Involves the injection of dye directly into the biliary tract.
- can be carried out even in the presence of liver dysfunction & jaundice.
- useful for distinguishing jaundice caused by liver disease from that caused by biliary obstruction
- for investigating the g.i symptoms of a patient whose gallbladder has been removed, for locating stones within the bile ducts, & for diagnosing cancer involving the biliary system.

# Percutaneous transhepatic cholangiography PTC



- Performed under moderate sedation on a patient who has been fasting; the patient receives local anesthesia & IV sedation.
- Coagulation parameters & platelet count should be normal .
- Broad-spectrum antibiotics are administered
- flexible needle is inserted into the liver from the right side in the midclavicular line immediately beneath the right costal margin.
- Successful entry of a duct is noted when bile is aspirated or upon the injection of a contrast agent.
- Ultrasound guidance can be used.

- Bile is aspirated & samples are sent for bacteriology & cytology.
- A water-soluble contrast agent is injected to fill the biliary system. The fluoroscopy table is tilted & the patient repositioned to allow x-rays to be taken in multiple projections
- Note
- **Murphy sign-** It is indicator of gall bladder inflammation (acute pancreatitis). Pain on deep breath when the finger on under the liver border at the bottom of the rib cage. The inspiration causes the gallbladder to descend onto the fingers.

# MANAGEMENT

- Nutritional & supportive therapy
- Pharmacologic therapy
- Nonsurgical removal
- Surgical management
- Nursing management

# NUTRITIONAL & SUPPORTIVE THERAPY

- The diet immediately after an episode is usually limited to low-fat liquids.
- Include powdered supplements ↑ protein & carbohydrate into skim milk.
- Cooked fruits, rice or tapioca, lean meats, mashed potatoes, non-gas-forming veg, bread, coffee or tea may be added as tolerated.
- Avoid eggs, cream, pork, fried foods, cheese, gas-forming vegetables & alcohol.



- Fatty foods may bring on an episode.
- Dietary management may be the major mode of therapy in patients who have had only dietary intolerance to fatty foods & vague g.i. symptoms

# PHARMACOLOGIC THERAPY

- Ursodeoxycholic acid (UDCA) , chenodeoxycholic acid (chenodiol or CDCA).
- Acts by inhibiting the synthesis & secretion of cholesterol, thereby desaturating bile.
- Existing stones can be reduced in size, small ones dissolved & new stones prevented from forming.

- 6 to 12 months of therapy are required.
- The effective dose of medication depends on body weight.
- This method of treatment is generally indicated for patients who refuse surgery or for whom surgery is considered too risky.
- Patients with significant, frequent symptoms, cystic duct occlusion, or pigment stones are not candidates for this therapy.
- Symptomatic patients with acceptable operative risk are more appropriate for laparoscopic or open cholecystectomy.

# NONSURGICAL REMOVAL OF GALLSTONES

- Dissolving Gallstones
- Stone Removal by Instrumentation
- Extracorporeal Shock-Wave Lithotripsy
- Intracorporeal Lithotripsy

# DISSOLVING GALLSTONES

- By infusion of a solvent (mono-octanoin or methyl tertiary butyl ether [MTBE]) into the gallbladder.
- Can be infused through a tube or catheter inserted percutaneously directly into the gallbladder; a tube or drain inserted through a T-tube tract to dissolve stones not removed at the time of surgery; an ERCP endoscope; or a transnasal biliary catheter.

- In the latter procedure, the catheter is introduced through the mouth & inserted into the CBD. The upper end of the tube is then rerouted from the mouth to the nose & left in place.
- This enables the patient to eat & drink normally while passage of stones is monitored or chemical solvents are infused to dissolve the stones.
- This method of dissolution of stones is not widely used in patients with gallstone disease.
- Method used when the size of stone not more than 20 mm in diameter.

# STONE REMOVAL BY INSTRUMENTATION

- used to remove stones that were not removed at the time of cholecystectomy or have become lodged in the CBD.
- A catheter & instrument with a basket attached are threaded through the T-tube tract or fistula formed at the time of T-tube insertion; the basket is used to retrieve & remove the stones lodged in the common bile duct.
- A second procedure involves the use of the ERCP endoscope .After the endoscope is inserted, a cutting instrument is passed through the endoscope into the ampulla of Vater of CBD.

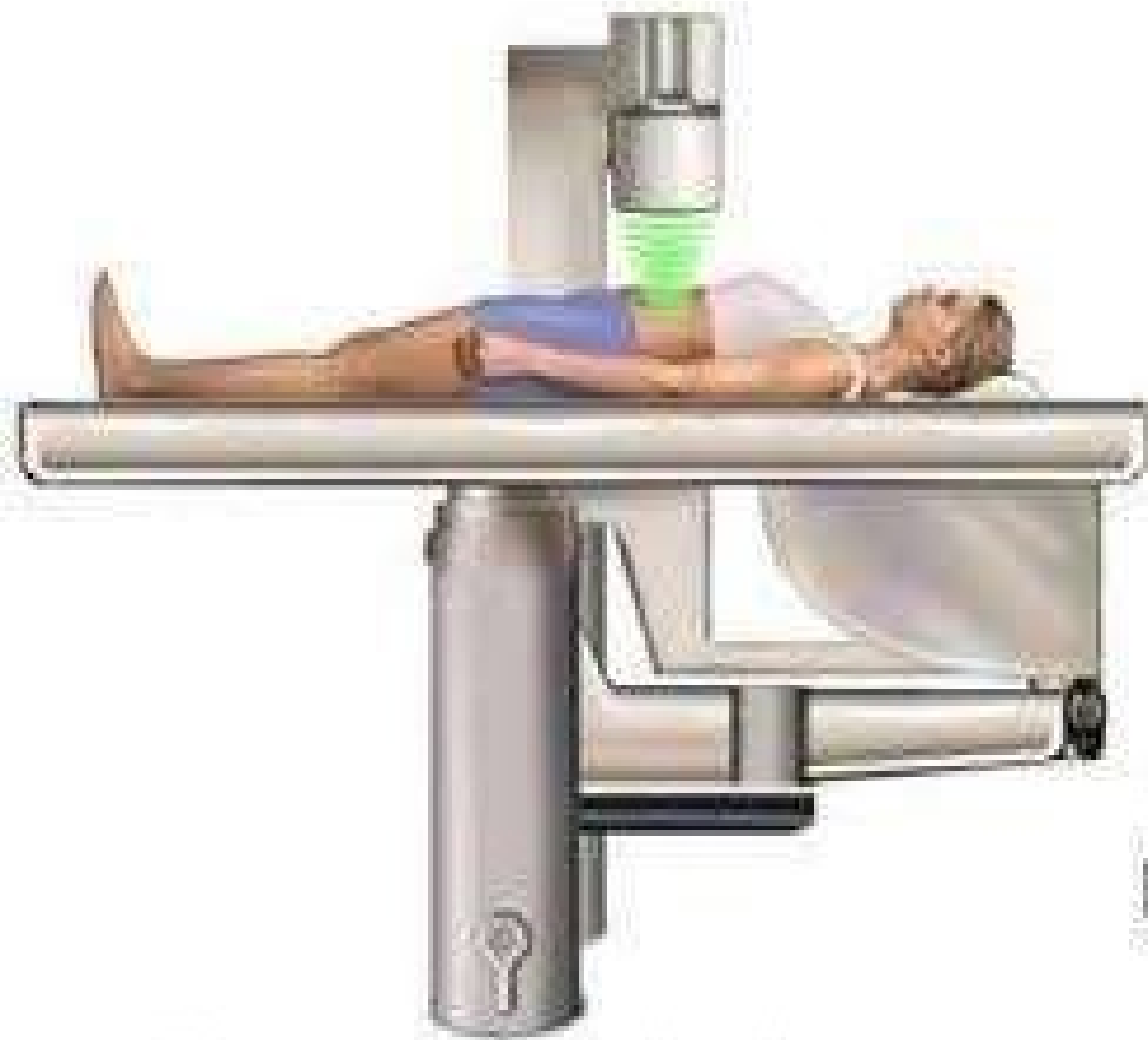
- Another instrument with a small basket or balloon at its tip may be inserted through the endoscope to retrieve the stones.
- The patient is closely observed for bleeding, perforation & the development of pancreatitis or sepsis.
- The ERCP procedure is particularly useful in the diagnosis & treatment of patients who have symptoms after biliary tract surgery, for patients with intact gallbladders, & for patients in whom surgery is particularly hazardous.



# EXTRACORPOREAL SHOCK-WAVE LITHOTRIPSY

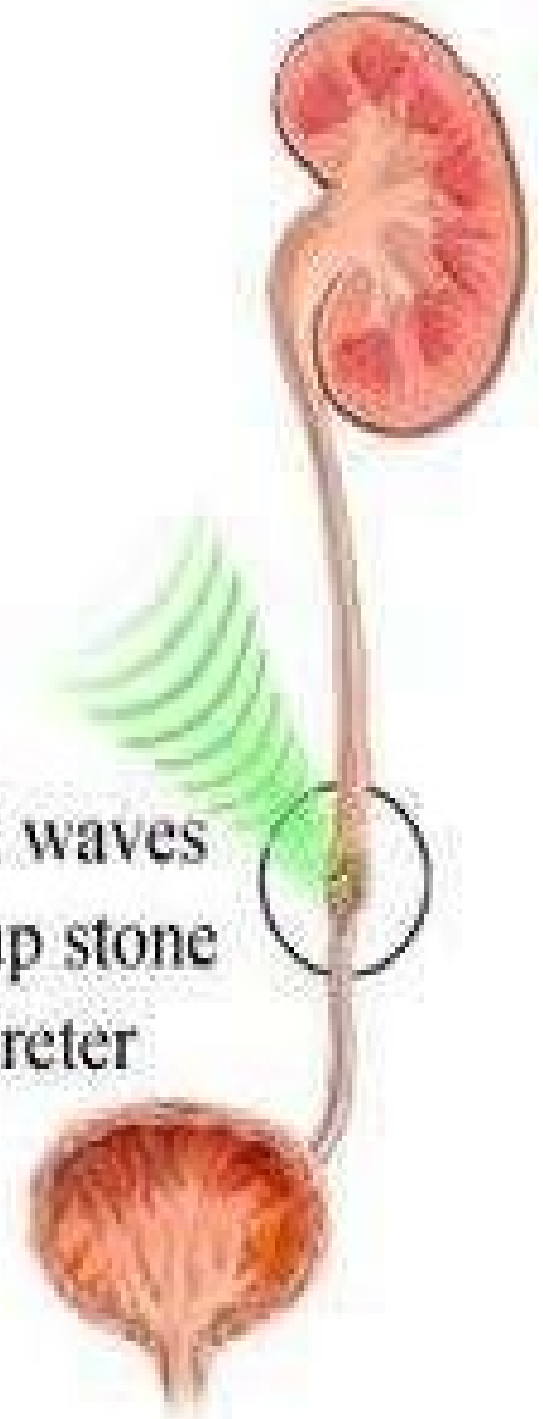- Used for nonsurgical fragmentation of gallstones.
- Derived from lithos, meaning stone & tripsis, meaning rubbing or friction.
- Uses repeated shock waves directed at the gallstones in the gallbladder or CBD to fragment the stones.
- The energy is transmitted to the body through a fluid-filled bag, or it may be transmitted while the patient is immersed in a water bath.

- Converging shock waves are directed to the stones to be fragmented.
- After the stones are gradually broken up, the stone fragments pass from the gallbladder or CBD spontaneously are removed by endoscopy, or dissolved with oral bile acid or solvent.
- Requires no incision & no hospitalization, patients are usually treated as OPD , but several sessions are generally necessary.



Extracorporeal shock wave lithotripsy (ESWL) machine

Shock waves  
break up stone  
in ureter



# INTRACORPOREAL LITHOTRIPSY

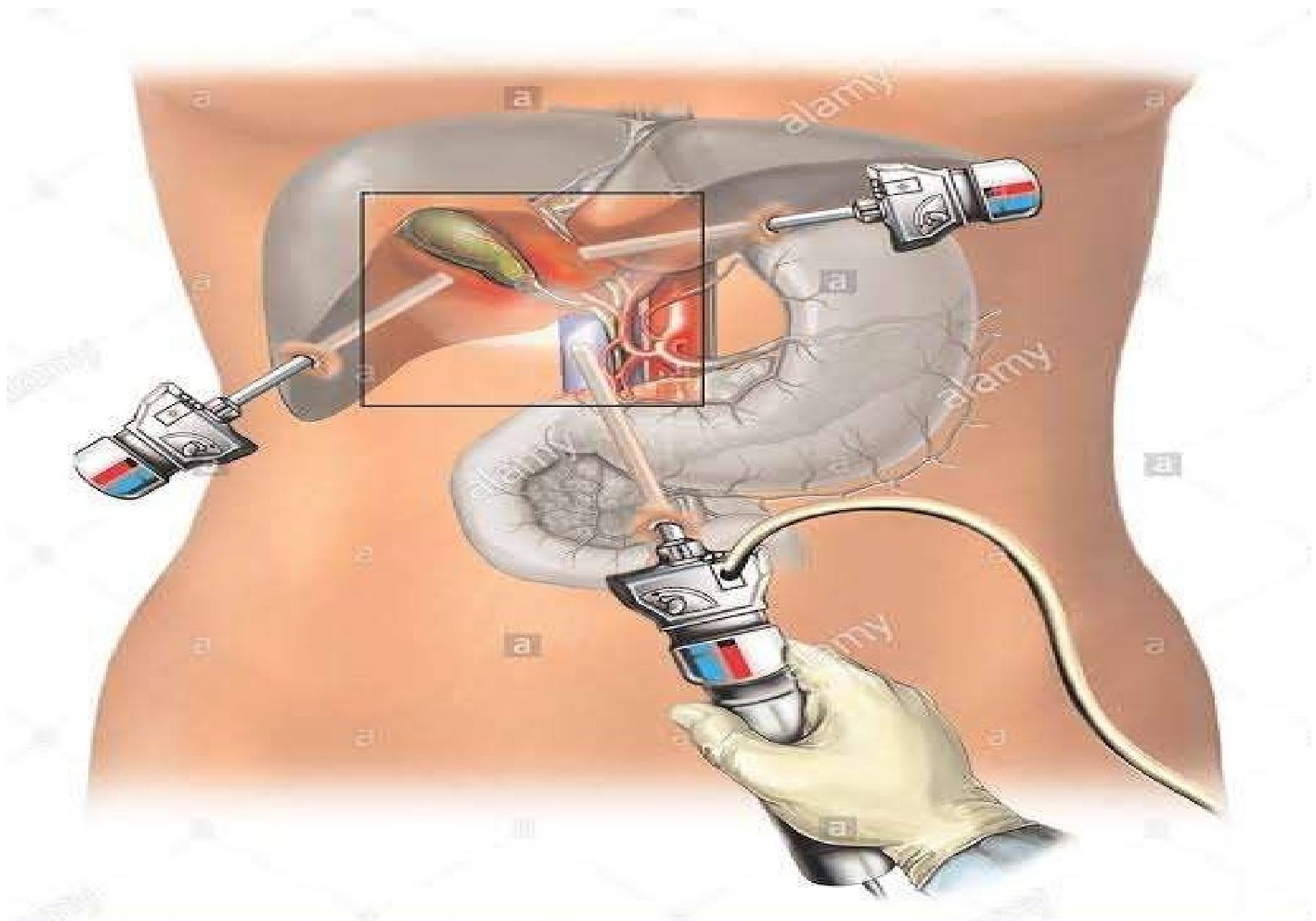
- Fragmented by means of laser pulse technology.
- A laser pulse is directed under fluoroscopic guidance with the use of devices that can distinguish between stones & tissue.
- Produces rapid expansion & disintegration of plasma on the stone surface, resulting in a mechanical shock wave.
- Electro- hydraulic lithotripsy uses a probe with two electrodes that deliver electric sparks in rapid pulses, creating expansion of the liquid environment surrounding the gallstones.

- This results in pressure waves that cause stones to fragment.
- Can be employed percutaneously with the use of a basket or balloon catheter system or by direct visualization through an endoscope.
- Repeated procedures may be necessary due to stone size, local anatomy, bleeding, or technical difficulty.
- A nasobiliary tube can be inserted to allow for biliary decompression & prevent stone impaction in the CBD. This approach allows time for improvement in the patient's clinical condition until gallstones are cleared endoscopically, percutaneously, or surgically.

# SURGICAL MANAGEMENT

# LAPAROSCOPIC CHOLECYSTECTOMY

- If the CBD is thought to be obstructed by a gallstone, an ERCP with sphincterotomy may be performed
- Performed through a small incision or puncture made through the abdominal wall in the umbilicus.





# CHOLECYSTECTOMY

- Gallbladder is removed through an abdominal incision (usually right subcostal) after the cystic duct & artery are ligated.
- Performed for acute & chronic cholecystitis.
- Drain may be placed close to the gallbladder bed & brought out through a puncture wound if there is a bile leak.
- Drain type is chosen based on the physician's preference.

# SMALL INCISION CHOLECYSTECTOMY

- Gallbladder is removed through a small incision.
- If needed, the surgical incision is extended to remove large gallbladder stones.
- Drains may or may not be used.
- The cost savings resulting from the shorter hospital stay have been identified as a major reason for pursuing this type of procedure.
- The procedure is controversial because it limits exposure to all the involved biliary structures.

# CHOLEDOCHOSTOMY

- An incision into the common duct, usually for removal of stones.
- After the stones have been evacuated, a tube usually is inserted into the duct for drainage of bile until edema subsides.
- This tube is connected to gravity drainage tubing, the patient is monitored closely.
- A laproscopic cholecystectomy is planned for a future date after acute inflammation has resolved.

# SURGICAL CHOLECYSTOSTOMY

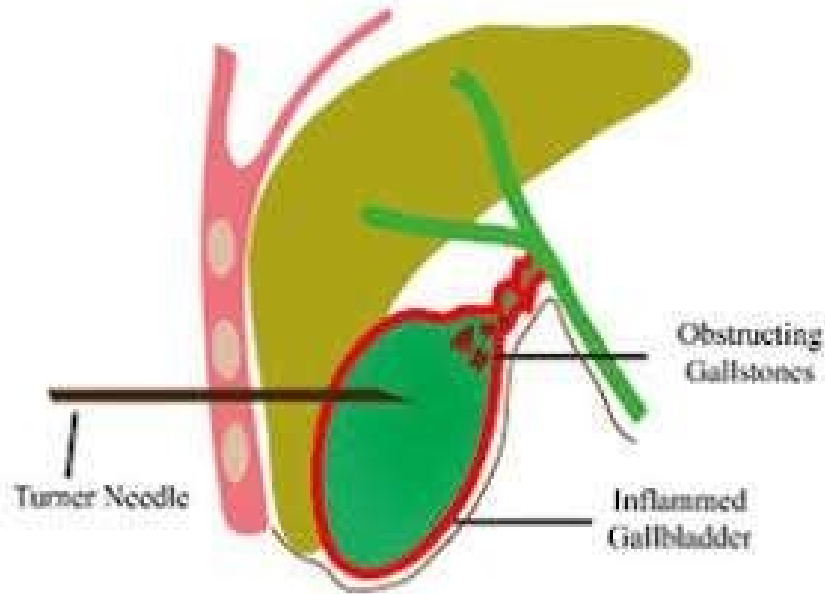
- Performed when the patient's condition prevents more extensive surgery or when an acute inflammatory reaction is severe.
- The gallbladder is surgically opened, the stones & the bile or the purulent drainage are removed & a drainage tube is secured with a purse-string suture.
- The drainage tube is connected to a drainage system to prevent bile from leaking around the tube or escaping into the peritoneal cavity.

# PERCUTANEOUS CHOLECYSTOSTOMY

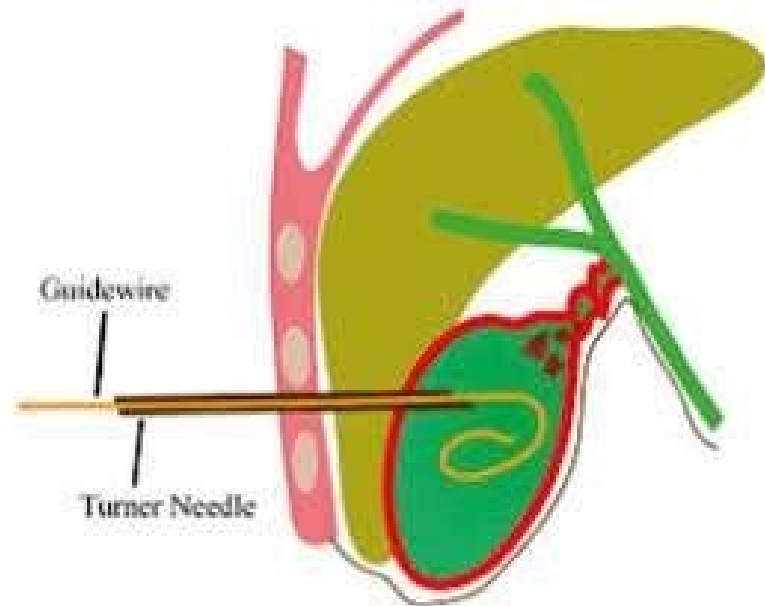
- Used in the treatment & diagnosis of acute cholecystitis in patients who are poor risks for any surgical procedure or for general anesthesia.
- Under local anesthesia, a fine needle is inserted through the abdominal wall & liver edge into the gallbladder under the guidance of ultrasound or computed tomography.
- Bile is aspirated to ensure adequate placement of the needle & a catheter is inserted into the gallbladder to decompress the biliary tract.

# Percutaneous Cholecystostomy Procedure

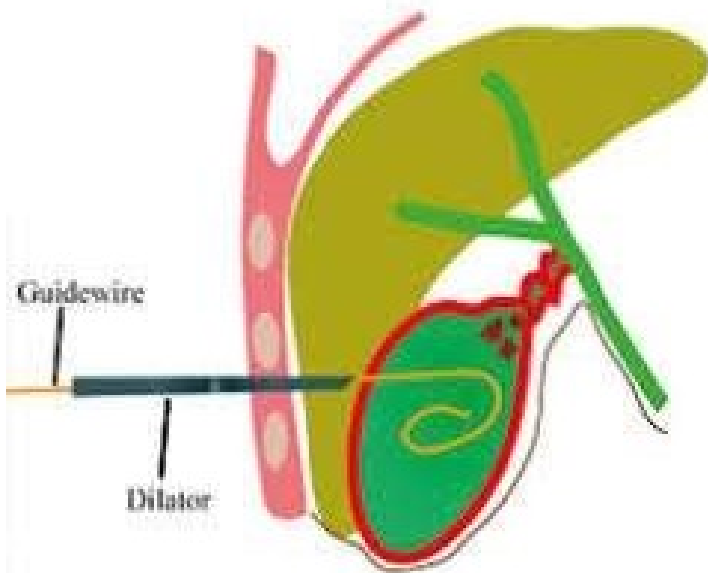
Step 1 - Placement of Turner Needle into Gallbladder



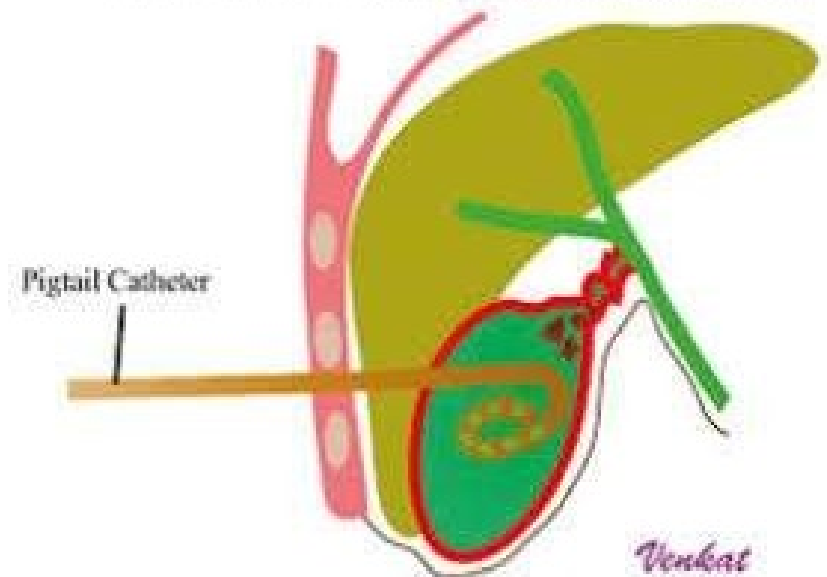
Step 2 - Placement of Guidewire through Turner Needle



Step 3 - Dilation of Tract with Dilators over Guidewire



Step 4 - Placement of Catheter over Guidewire



# NURSING DIAGNOSIS

- Acute pain & discomfort r/t surgical incision.
- Impaired gas exchange r/t the high abdominal surgical incision
- Impaired skin integrity r/t altered biliary drainage after surgical intervention
- Imbalanced nutrition, less than body requirements, r/t inadequate bile secretion
- Deficient knowledge about self-care activities r/t incision care, dietary modifications (if needed), medications, reportable signs or symptoms (eg, fever, bleeding, vomiting)

# PLANNING & GOALS

- Relief of pain
- Adequate ventilation.
- Intact skin & improved biliary drainage.
- Optimal nutritional intake.
- Absence of complications.
- Understanding of self-care routines.



# RELIEVING PAIN

- Observe & document location, severity (0–10 scale) & character of pain (steady, intermittent, colicky).
- Splint the affected site & to take shallow breaths to prevent pain.
- Gradually increased activity .
- Administer analgesic agents as prescribed.
- Helping the patient to turn, cough, breathe deeply & ambulate as indicated.
- Use of a pillow or binder over the incision.

- Control environmental temperature.
- Encourage use of relaxation techniques.
- Provide diversional activities.
- Make time to listen to and maintain frequent contact with patient.

# IMPROVING RESPIRATORY STATUS

- Reminds patients to take deep breaths & cough every hour to expand the lungs fully & prevent atelectasis.
- The early & consistent use of incentive spirometry.
- Early ambulation prevents pulmonary complications as well as other complications, such as thrombophlebitis.

# PROMOTING SKIN CARE & BILIARY DRAINAGE

- Drainage tubes must be connected immediately to a drainage receptacle.
- Fasten tubing to the dressings or to the patient's gown.
- Observe for indications of infection, leakage of bile into the peritoneal cavity, & obstruction of bile drainage.
- Note & report right upper quadrant abdominal pain, nausea & vomiting, bile drainage around any drainage tube, clay-colored stools, & a change in vital signs.

- To prevent total loss of bile, the drainage tube or collection receptacle is elevated above the level of the abdomen.
- Every 24 hours, measure the bile collected & records the amount, color, & character of the drainage. After several days of drainage, the tube may be clamped for an hour before & after each meal to deliver bile to the duodenum to aid in digestion. Within 7 to 14 days, the drainage tube is removed.
- The patient who goes home with a drainage tube in place requires instruction & reassurance about its function & care of the tube.

- Observes the stools daily & notes their color.
- Specimens of both urine & stool may be sent for examination for bile pigments.
- In this way, it is possible to determine whether the bile pigment is disappearing from the blood & is draining again into the duodenum.
- Maintaining a careful record of fluid intake & output is important.

# IMPROVING NUTRITIONAL STATUS

- Encourage the patient to eat a diet ↓ in fats & ↑ in carbohydrates & proteins immediately after surgery.
- Fat restriction usually is lifted in 4 to 6 weeks
- This is in contrast to before surgery, when fats may not be digested completely or adequately, & flatulence may occur.

# COMPLICATIONS GALL STONES

- Chronic cholecystitis
- Acute cholecystitis
- Choledocholithiasis
- Cholangitis,
- Gallstone pancreatitis,
- Gallstone ileus,
- Perforation of the gallbladder
- Gallbladder carcinoma



# MANAGING COMPLICATIONS

- Bleeding
- Postop, monitor vital signs & inspects the surgical incisions & drains for bleeding.
- Assess the patient for ↑ tenderness & rigidity of the abdomen. Report to the surgeon.
- Instruct to report any change in the color of stools.
- After lap.cholecystectomy, assess for loss of appetite, vomiting, pain, distention of the abdomen, & temperature elevation.

# PATIENT EDUCATION

## **Managing Pain**

- Sitting upright in bed or a chair or walking may ease the discomfort.
- Analgesic medications as needed & as prescribed
- Report to surgeon if pain is unrelieved even with analgesic use.

## **Resuming Activity-**

- Light exercise (walking) immediately.
- Shower or bath after 1 or 2 days.
- Drive a car after 3 or 4 days. Avoid lifting objects exceeding 5 pounds after surgery, usually for 1 week.

## **Caring for the Wound**

- Check puncture site daily for signs of infection. Wash puncture site with mild soap & water. Allow special adhesive strips on the puncture site to fall off. Do not pull them off.

## **Resuming Eating**

- Resume normal diet.
- If you had fat intolerance before surgery, gradually add fat back into your diet in small increments.

## **Follow-Up Care**

- Report any sign & symptoms of infection at or around the puncture site: redness, tenderness, swelling, heat, or drainage.
- Fever of 37.7°C (100°F) or more for 2 consecutive days.
- Nausea, vomiting, or abdominal pain

THANK YOU